

デジタルマンモグラフィランプリ【解説】

「総合司会」

県立広島病院

消化器・乳腺・移植外科 野間 翠

「マンモグラフィ解説」

国立病院機構姫路医療センター

放射線診断科 白岩美咲

「病理解説」

広島市立北部医療センター安佐市民病院

病理診断科 金子真弓

共催：株式会社ネットカムシステムズ



The Japanese Breast Cancer Society
since 1992



筆頭演者の利益相反状態の開示 すべての項目に該当なし

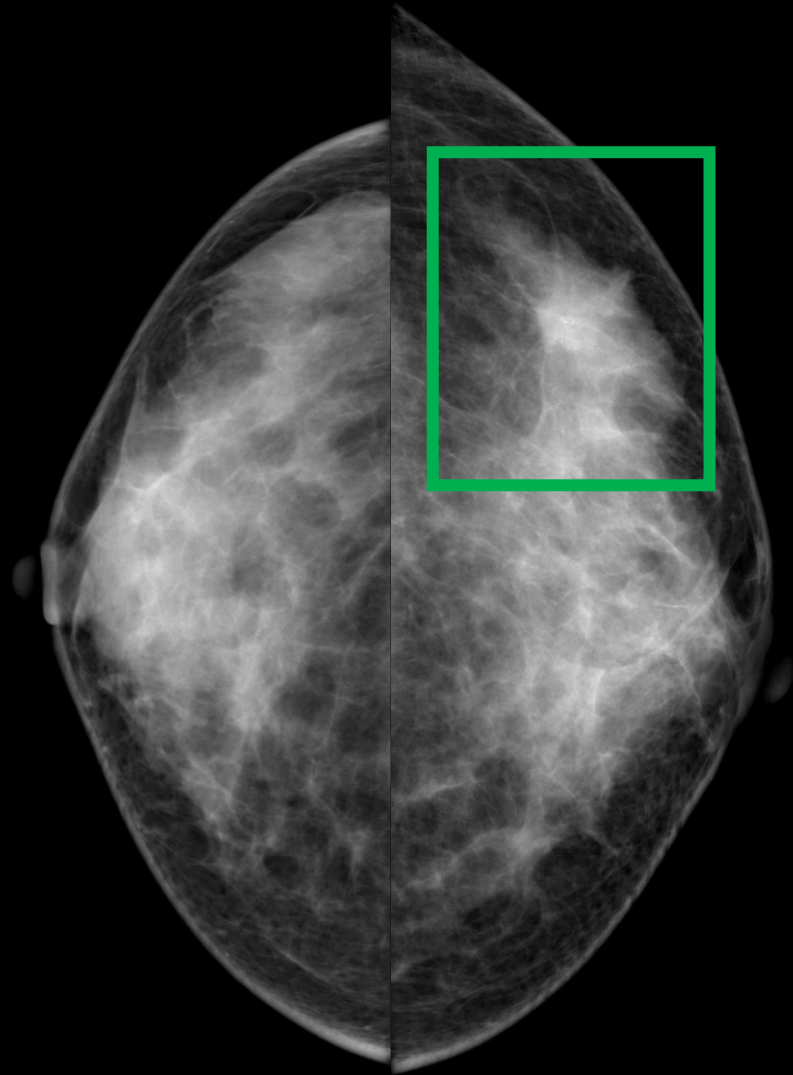
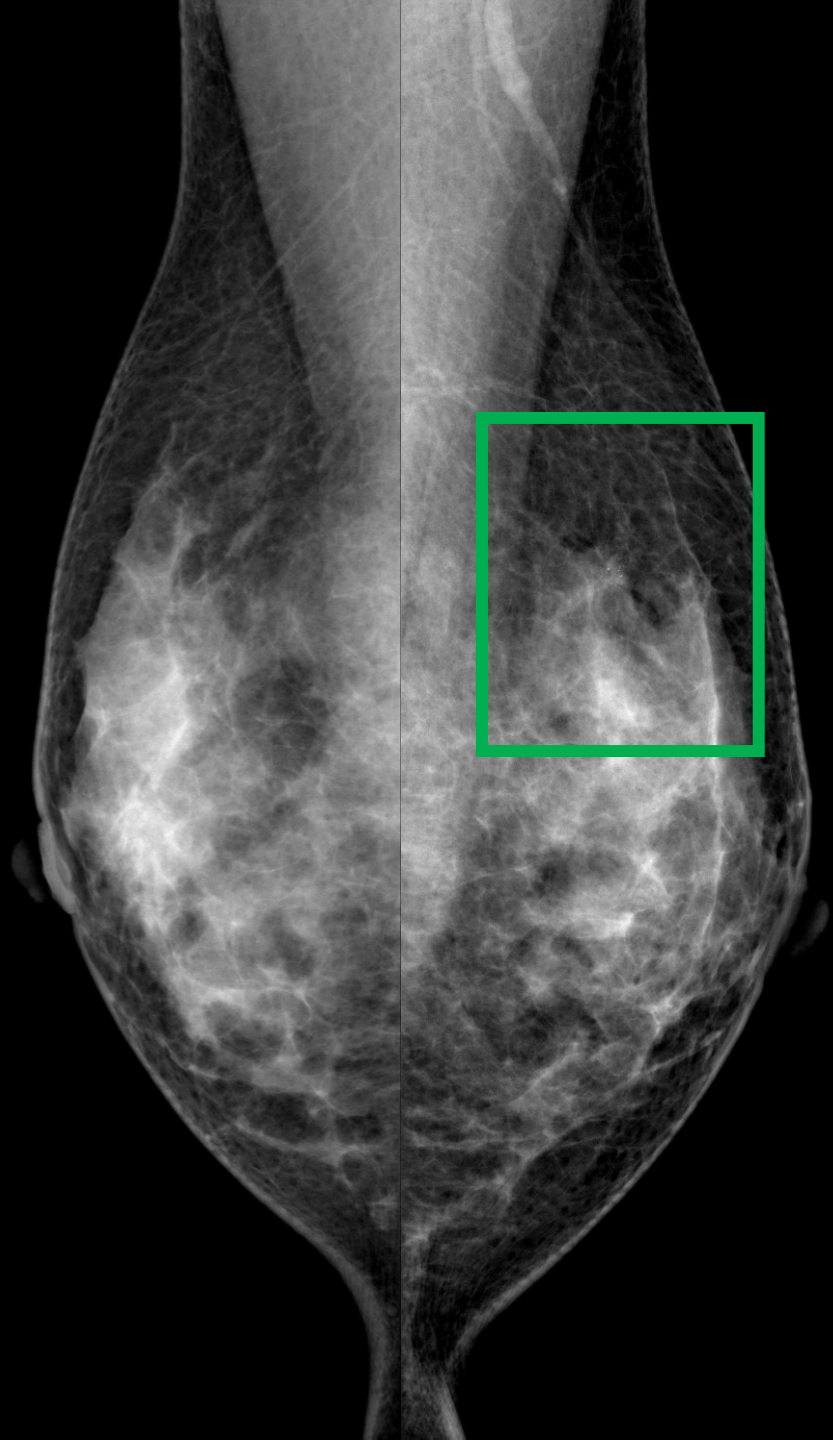
症例 1

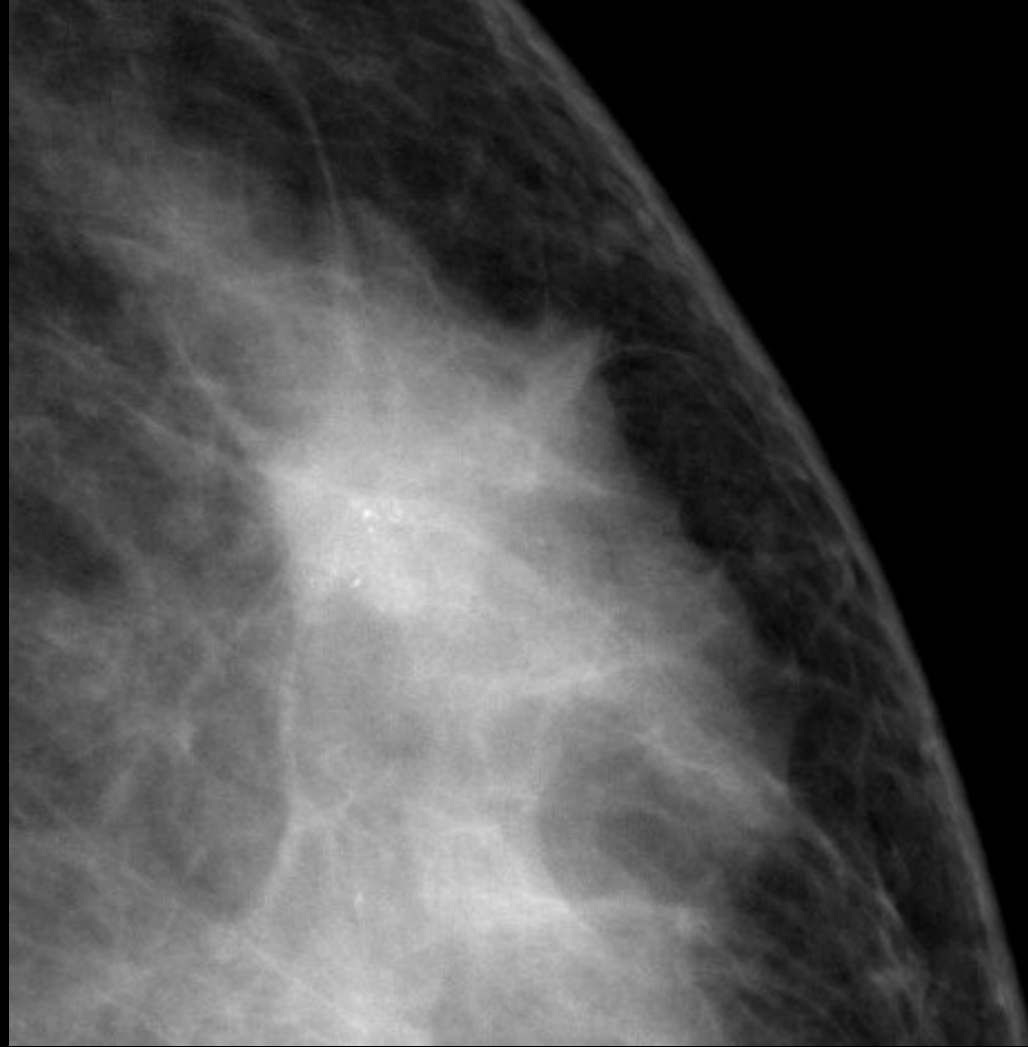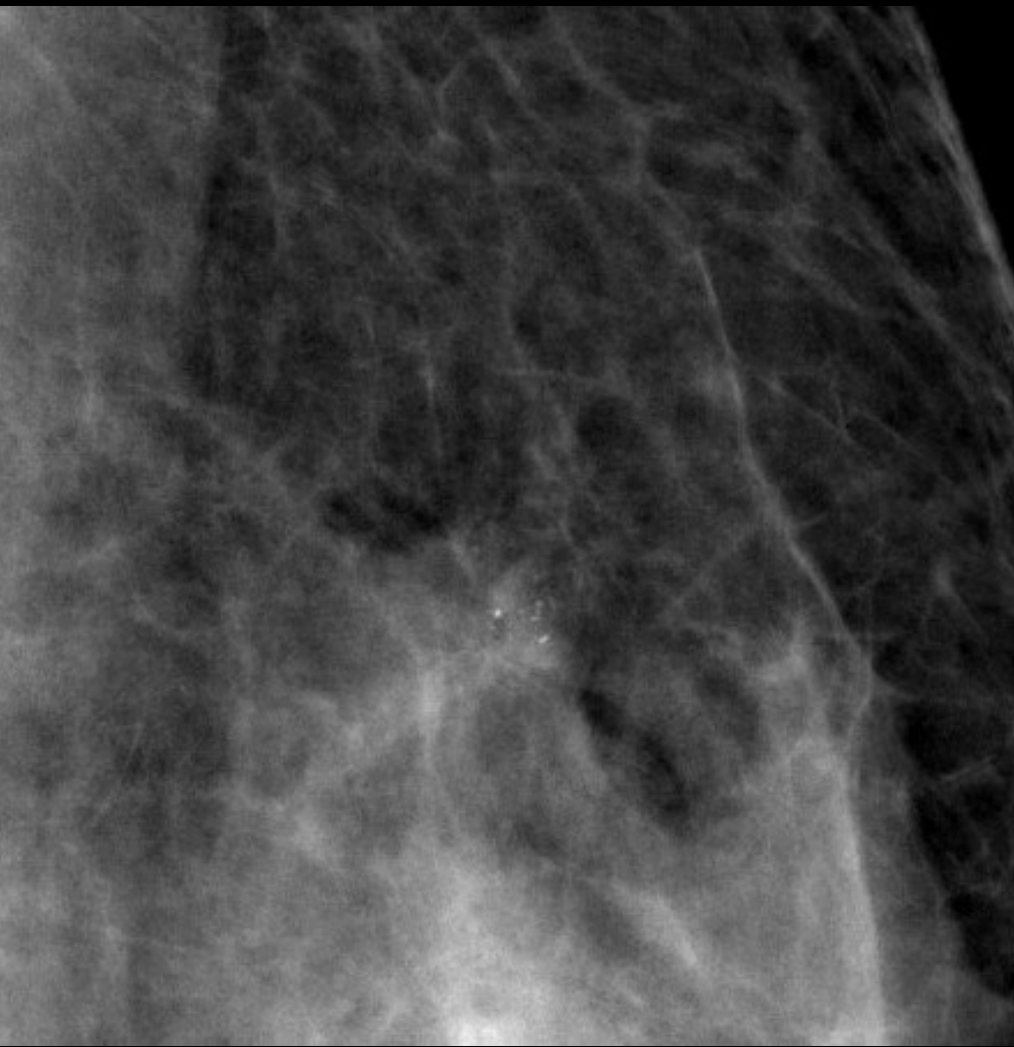カテゴリー 1 / 1

正常

症例 2

47歳 不均一高濃度





淡く不明瞭・角のとれた多形性石灰化の集簇像
背景に境界不明瞭・微細分葉鋸歯状の不整形腫瘍

カテゴリー 4

症例 2

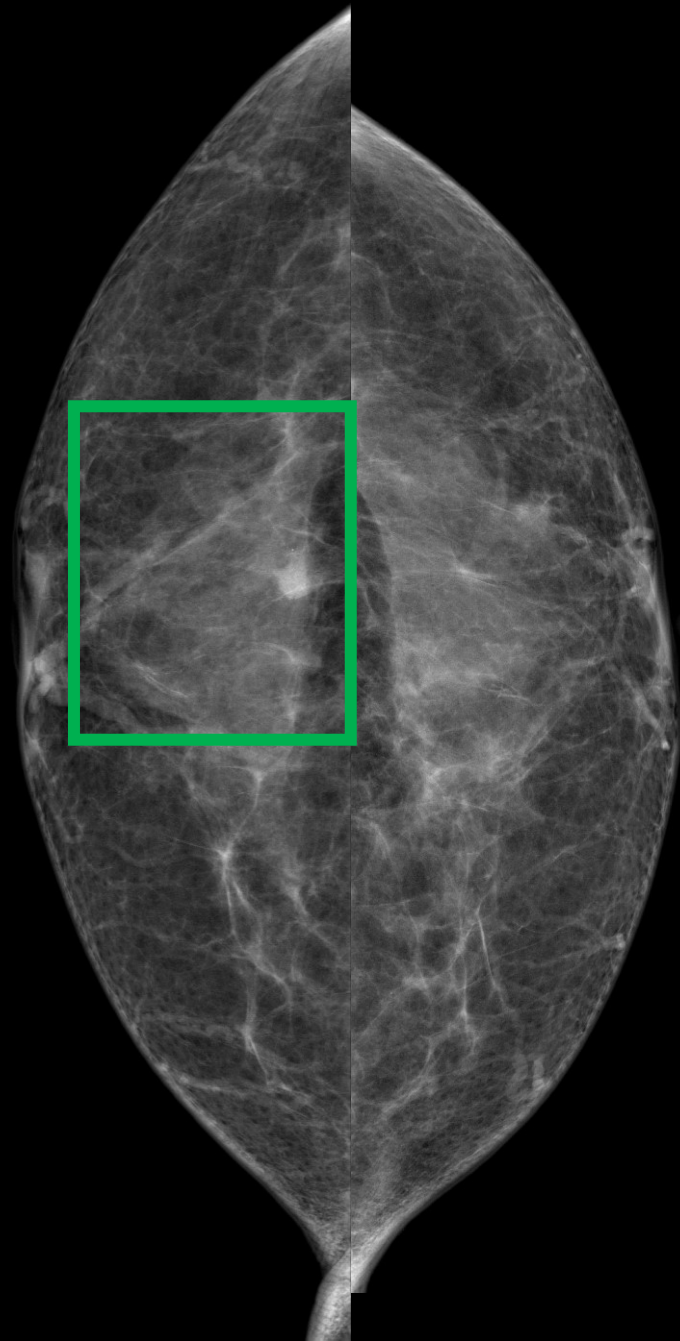
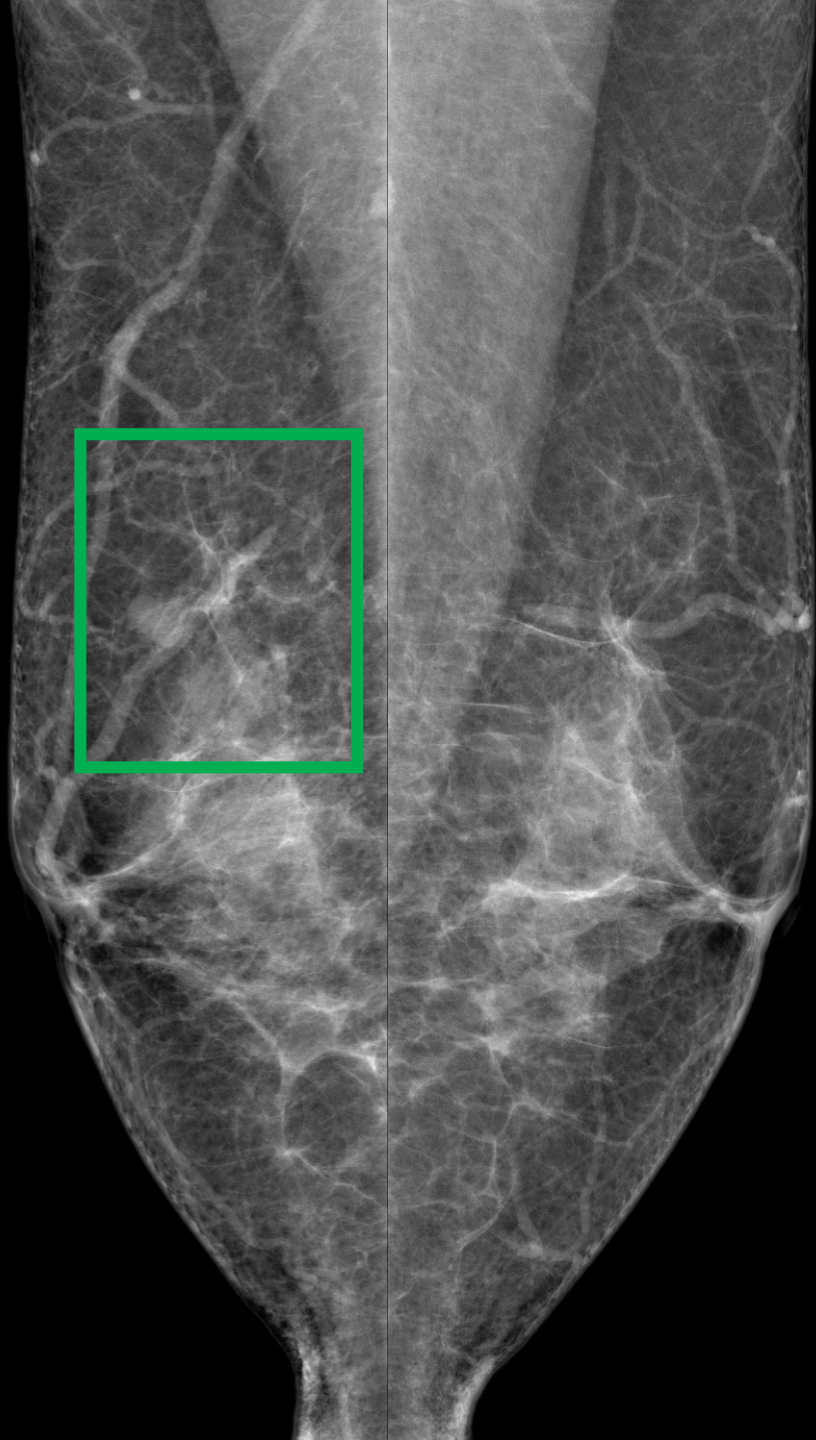
カテゴリー 1 / 4

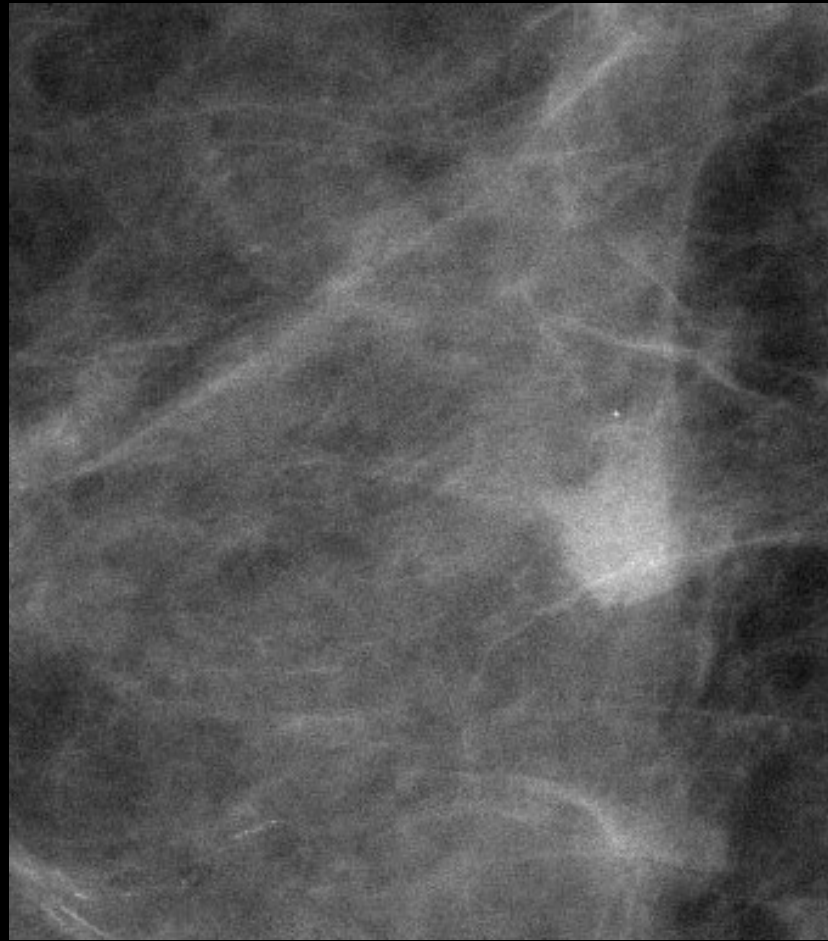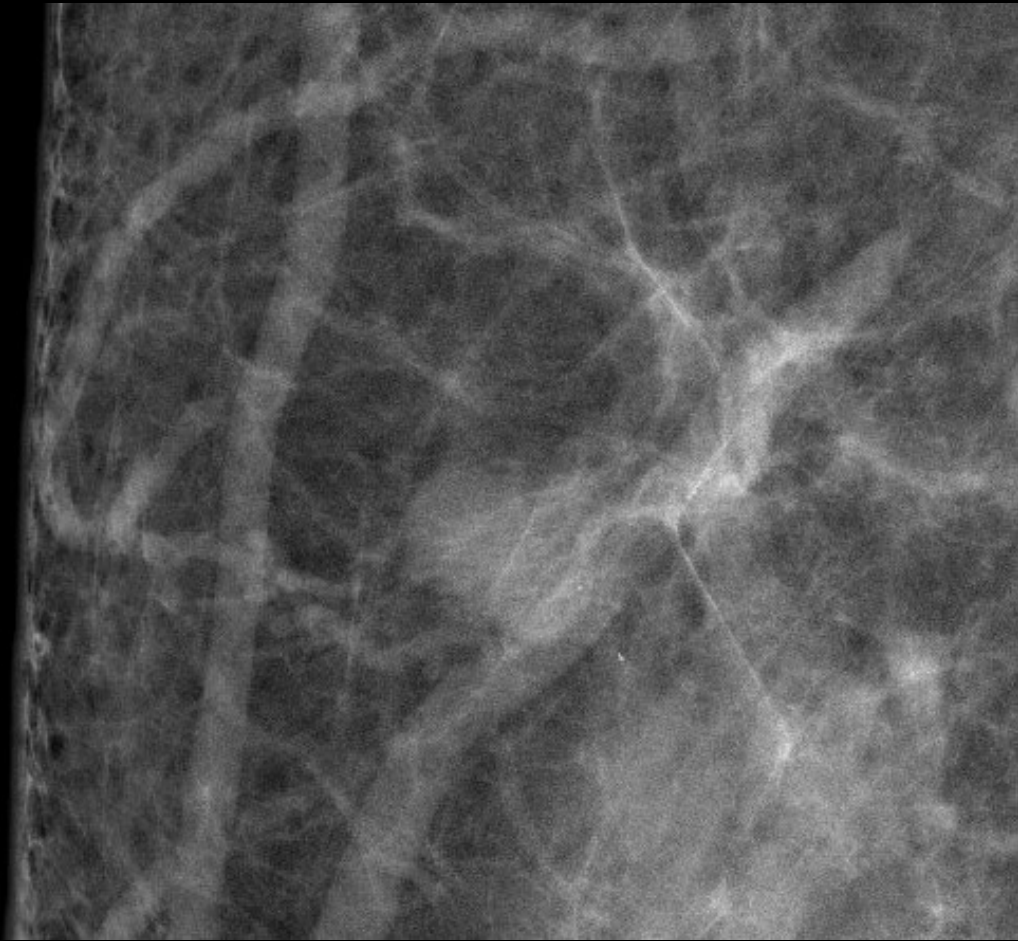
浸潤性乳管癌(硬性型)

T1cN1M0

症例 3

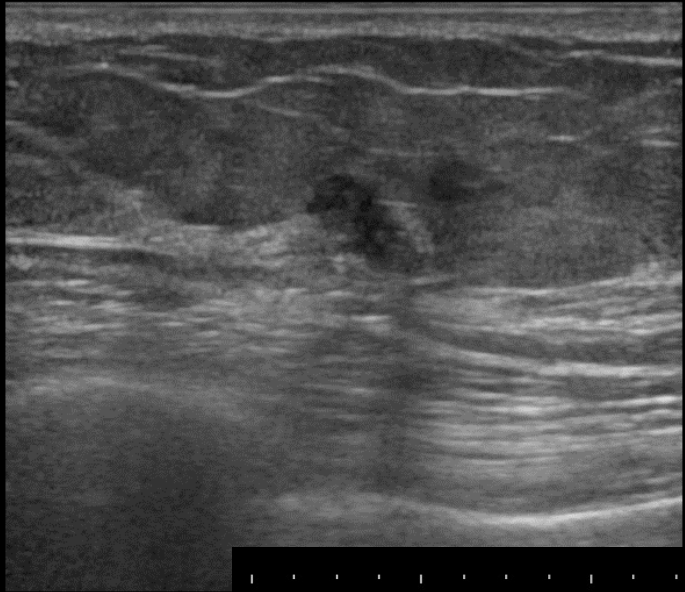
61歳 乳腺散在



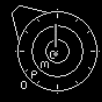

一部境界明瞭平滑、一部境界不明瞭な等～やや高濃度の円形腫瘍

カテゴリー 4

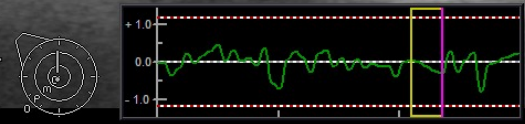
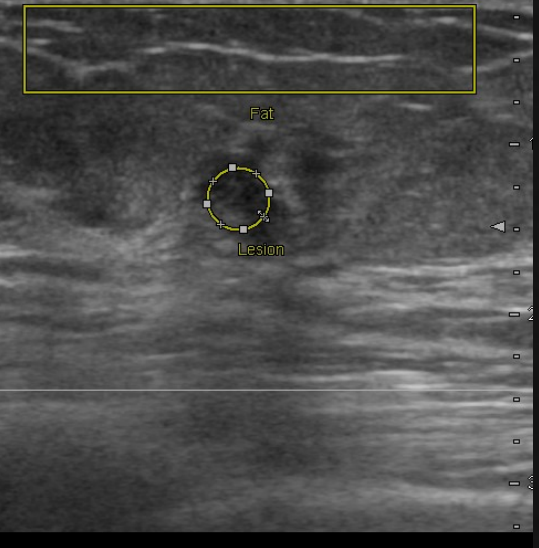
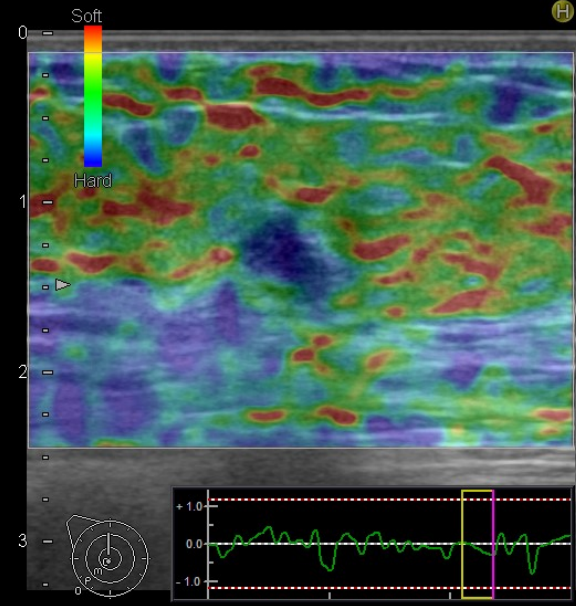


-0
-1
-2
-3



FR:21
L75

BG:12 DR:70
HdTHI-P



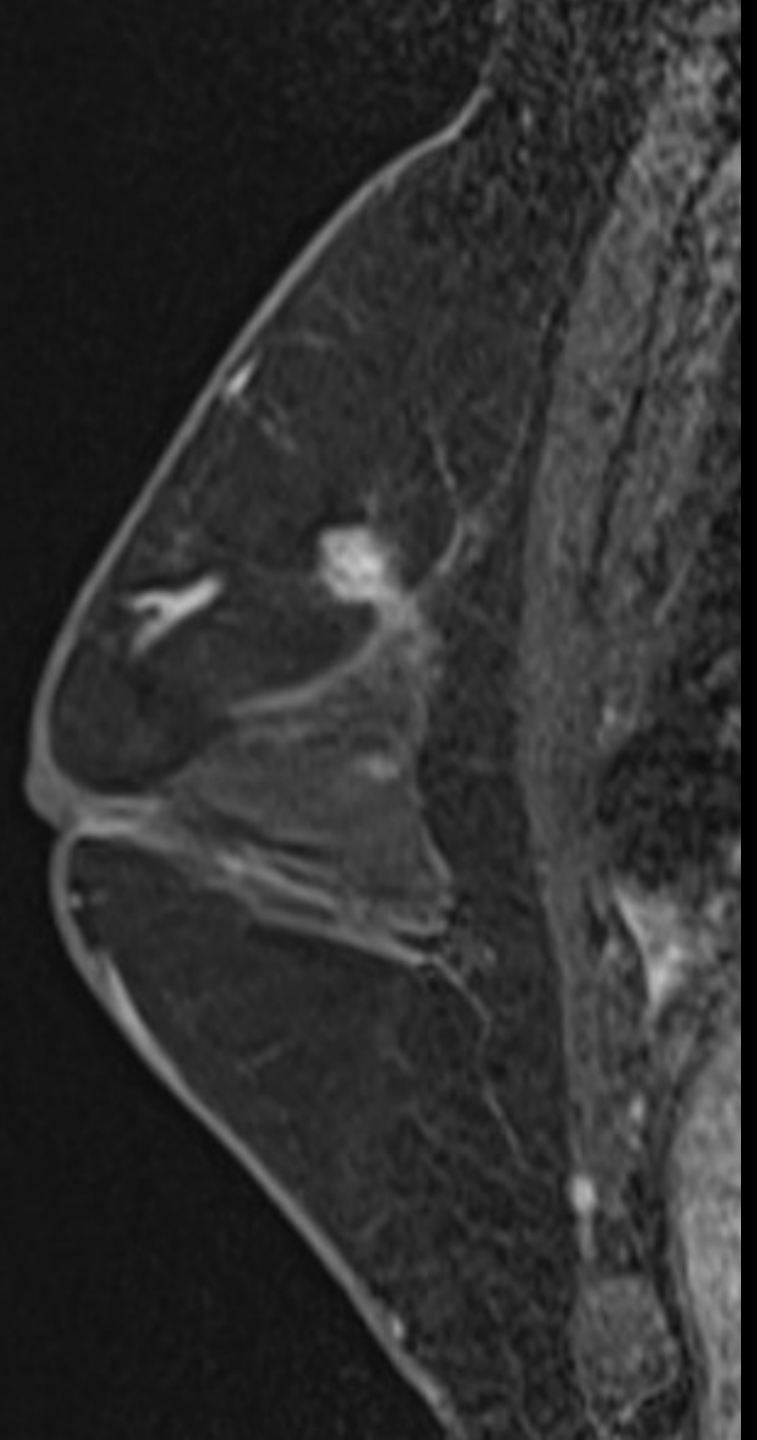
FLR	Fat	0.26 %	Lesion	0.04 %	FLR	7.00
FLR 4.3						

FR:15
L75

BG:12 DR:70 F.Rej:5 N.Rej:3
HdTHI-P BL.:26%

FR:15
L75


BG:12 DR:70
HdTHI-P

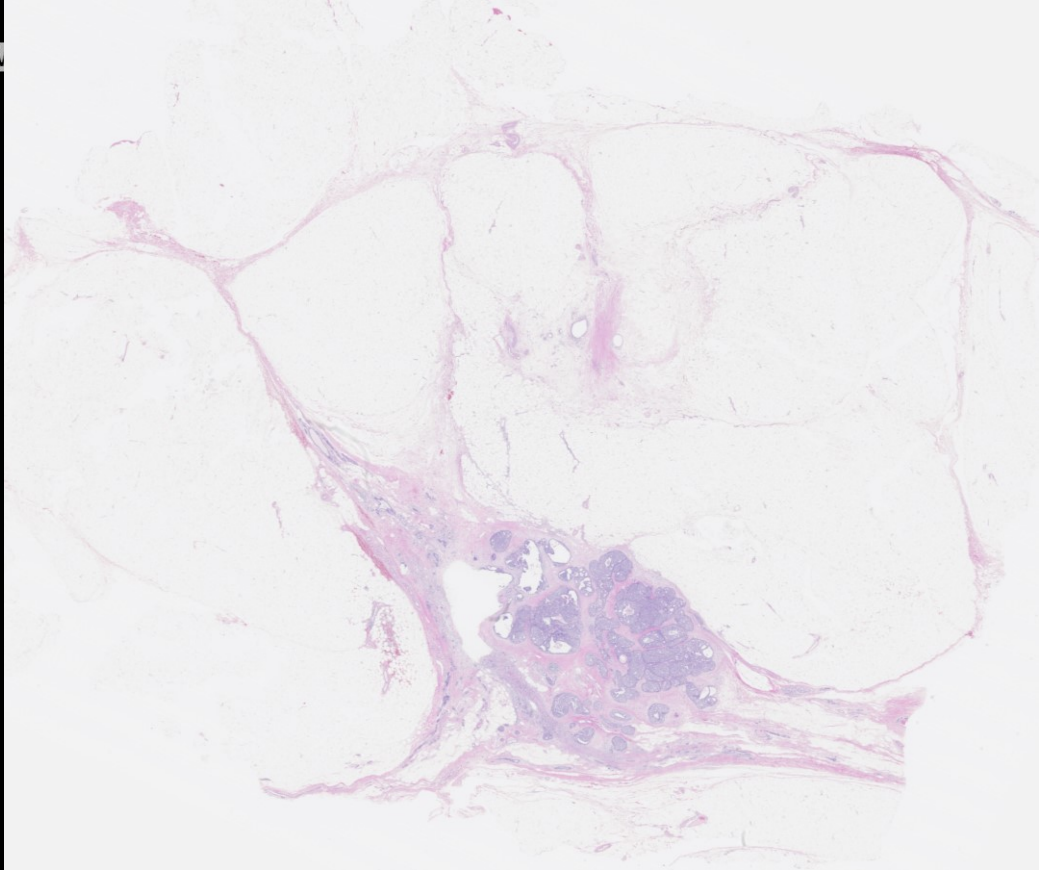
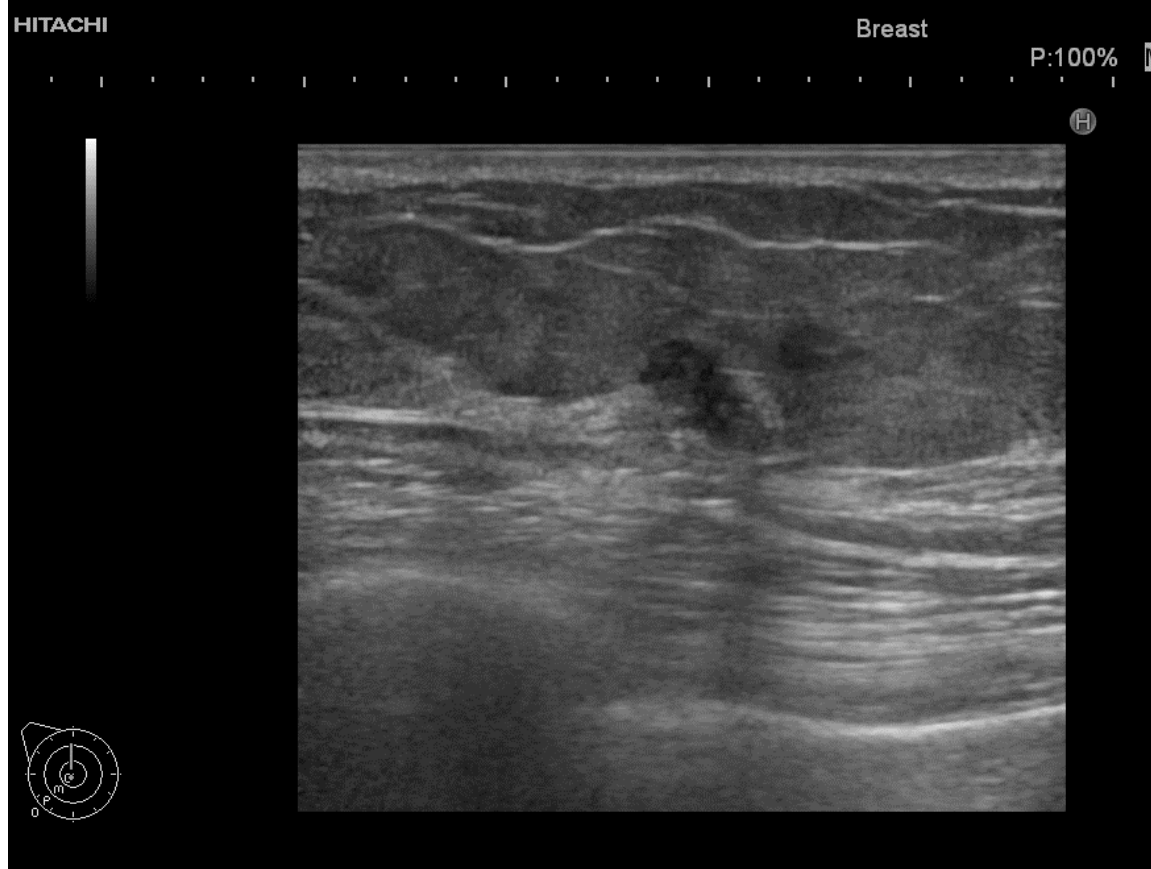


症例 3

カテゴリー 4 / 1

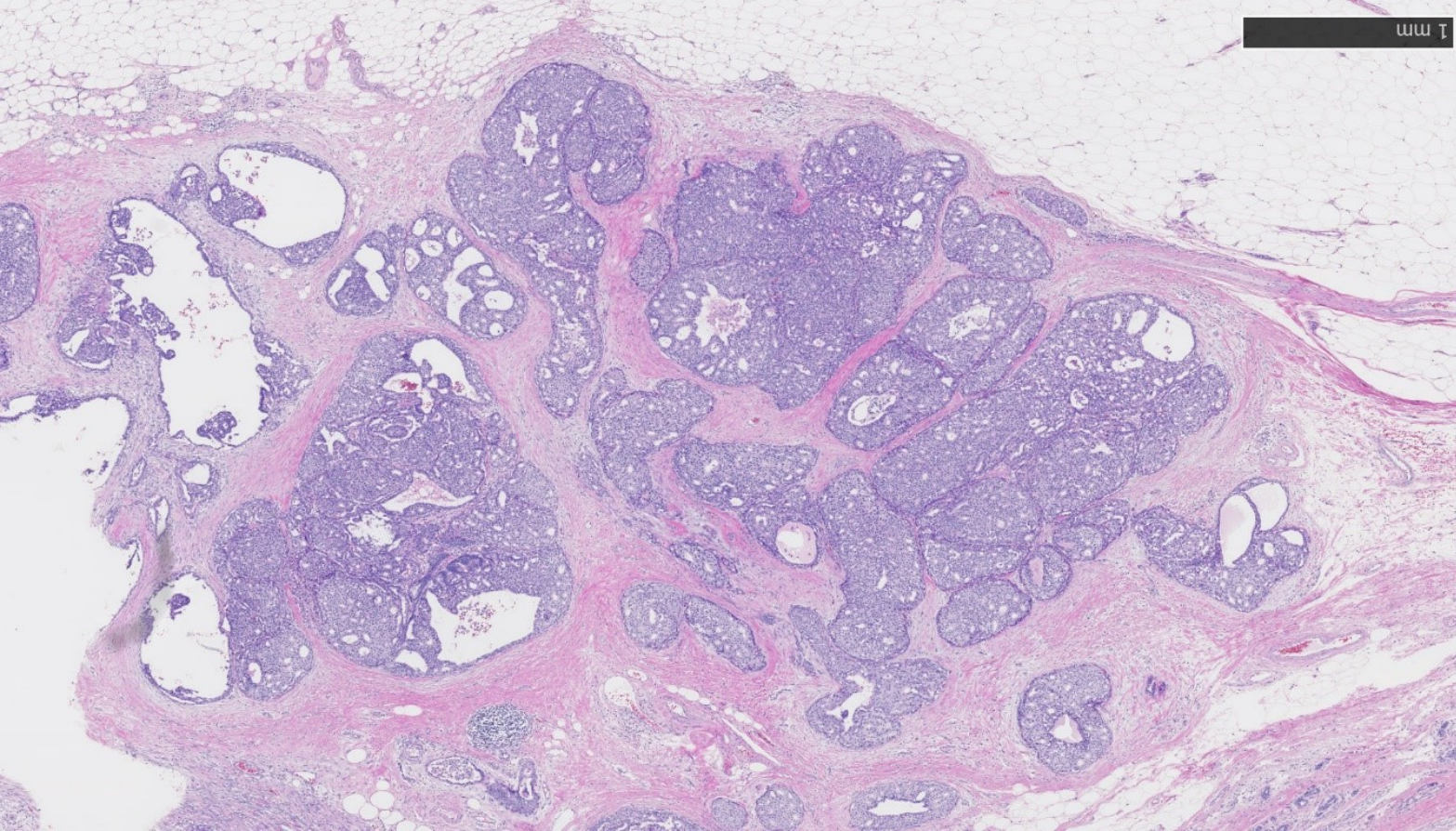
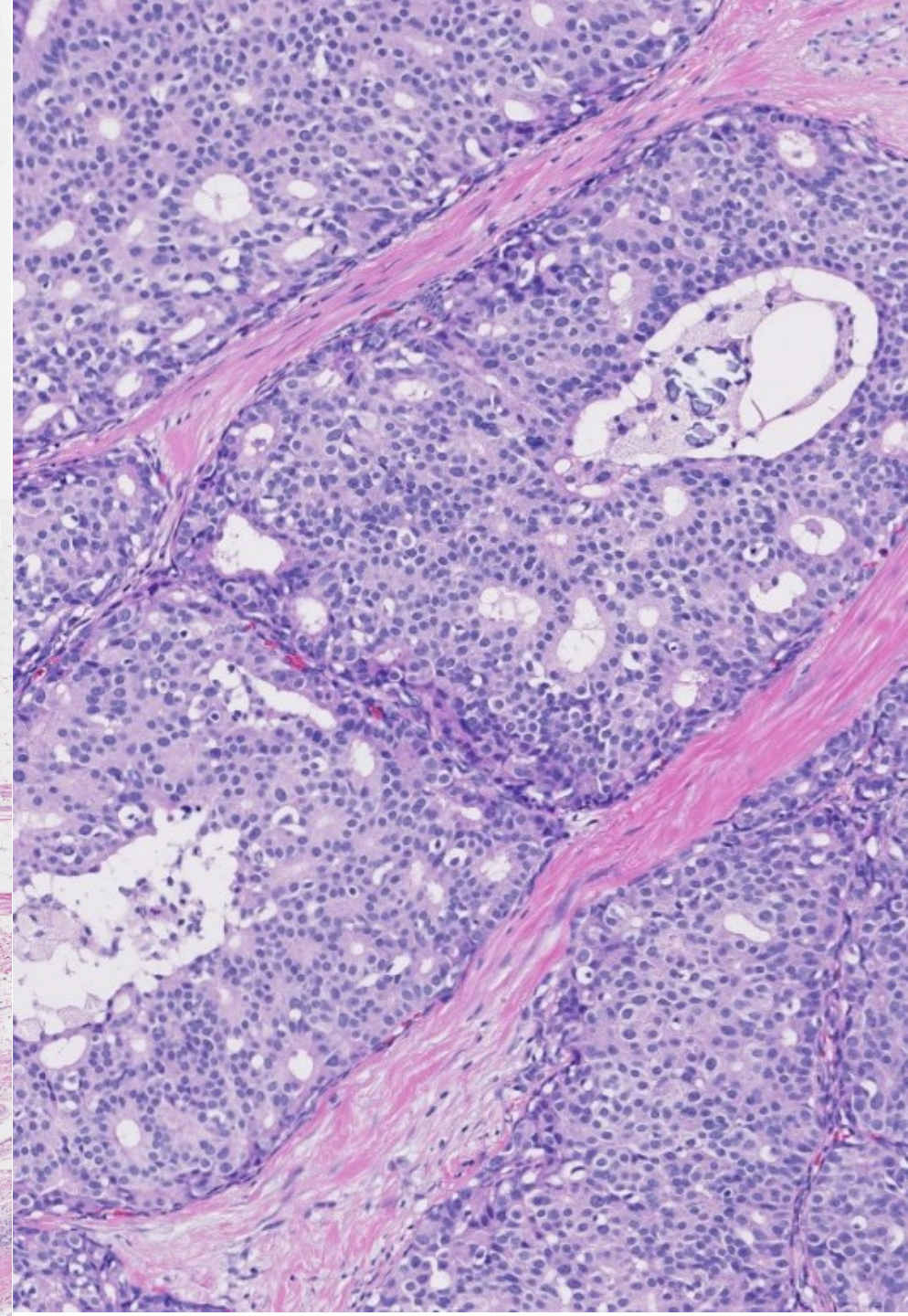
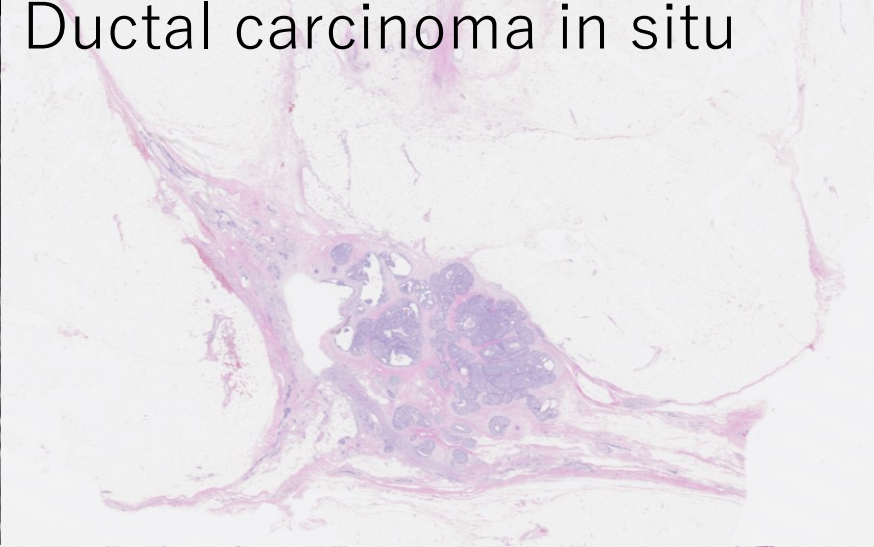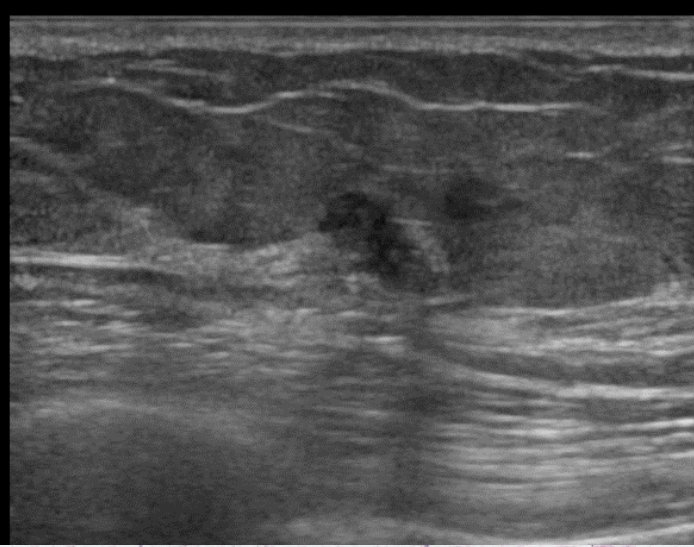
病理解説





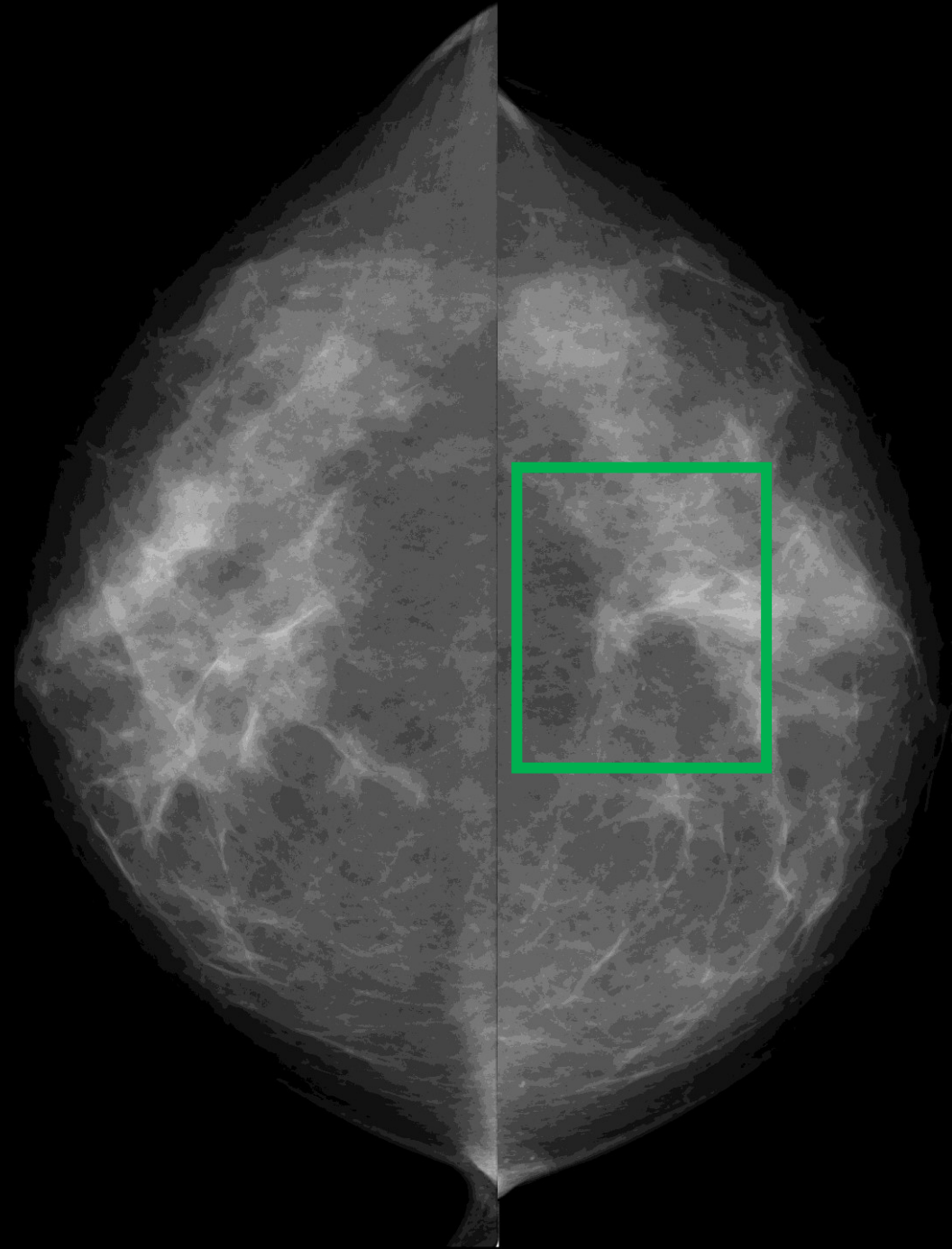
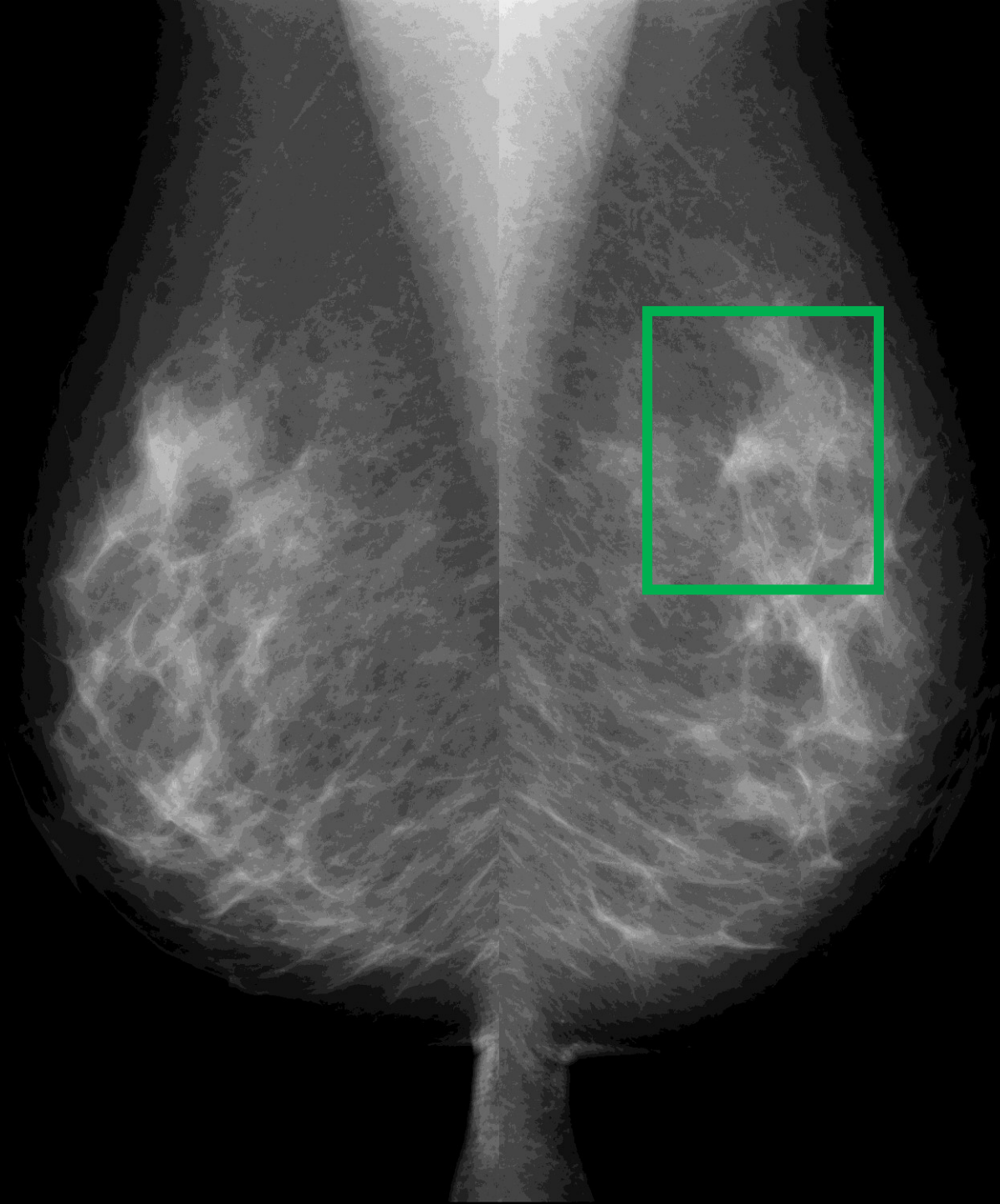
1. **Noninvasive ductal carcinoma** of right breast, AC area*, partial mastectomy
* 9X7X5mm, Cribriform type>papillary type, 断端(-)
2. Three lymph node, all negative for metastatic carcinoma*2, right sentinel, excised
3. Fibrocystic disease of right breast, mild

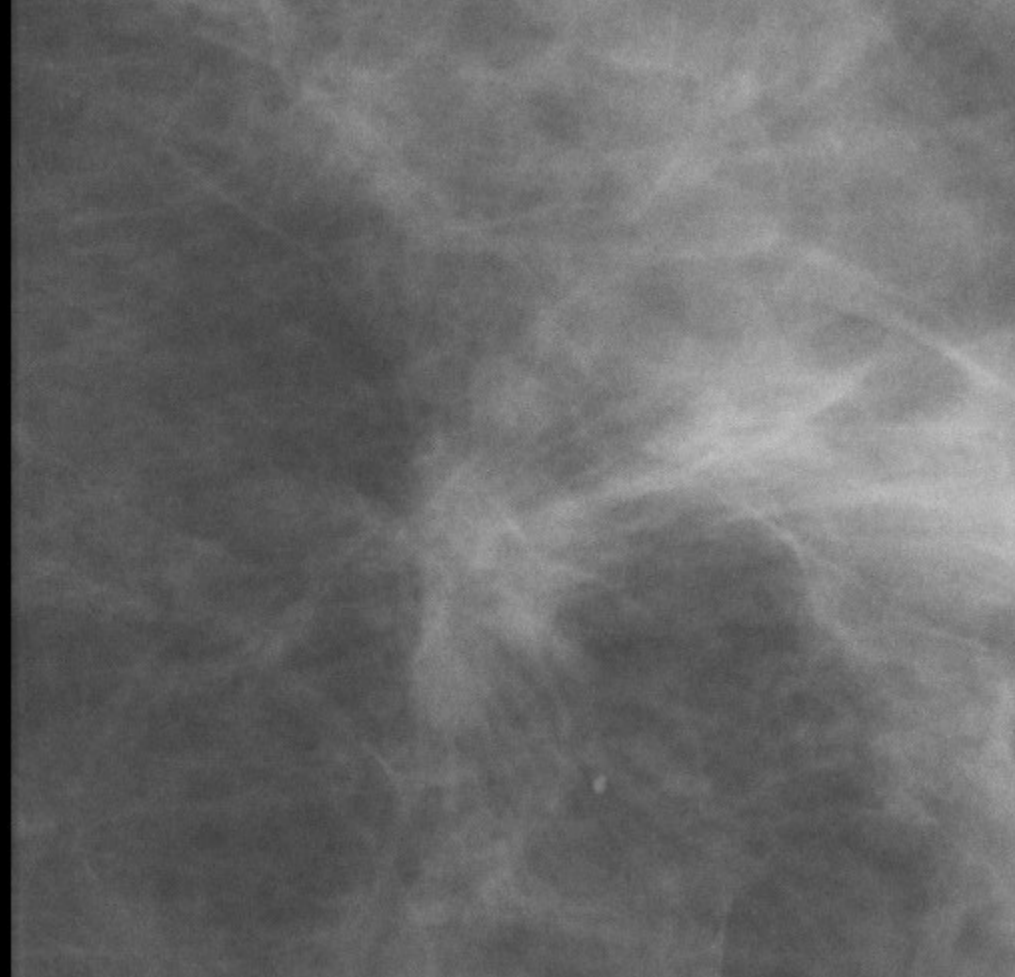
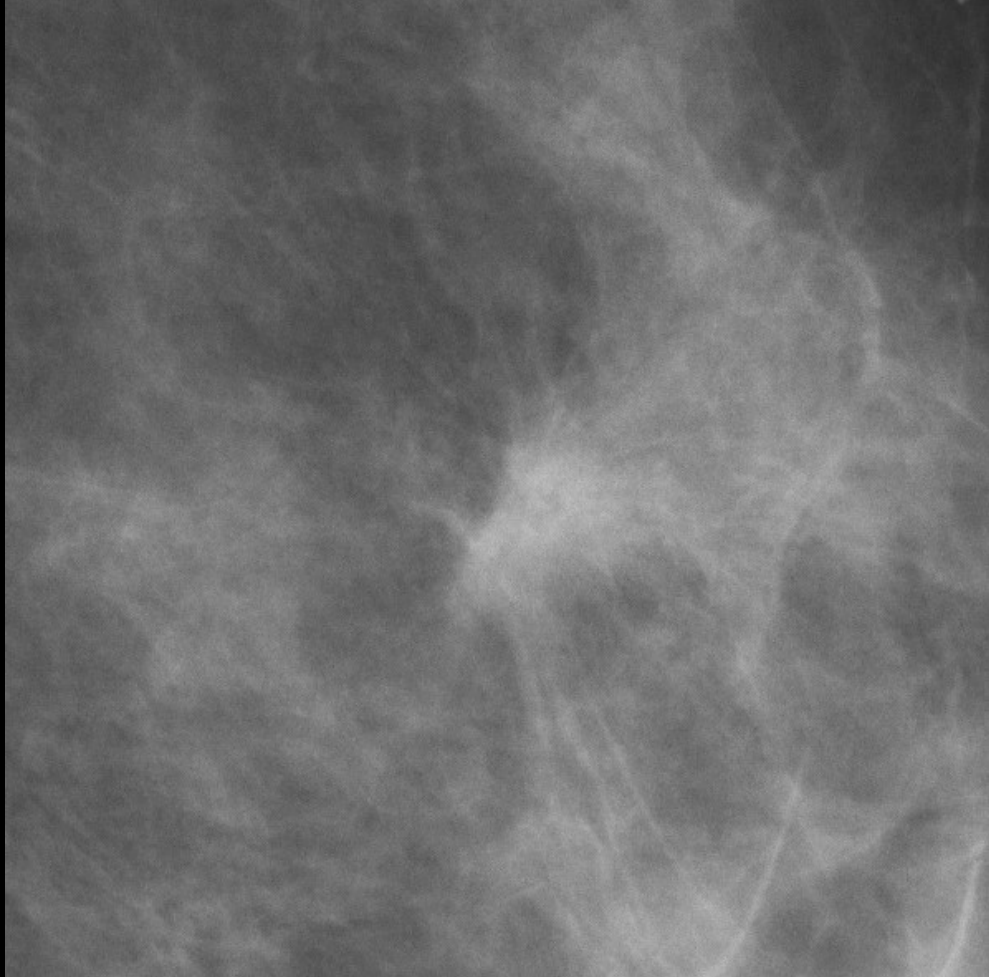
Ductal carcinoma in situ



症例 4

44歳 乳腺散在





スピキュラを有する不整形の等濃度腫瘤もしくは構築の乱れ

カテゴリー 4 5

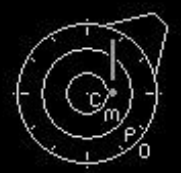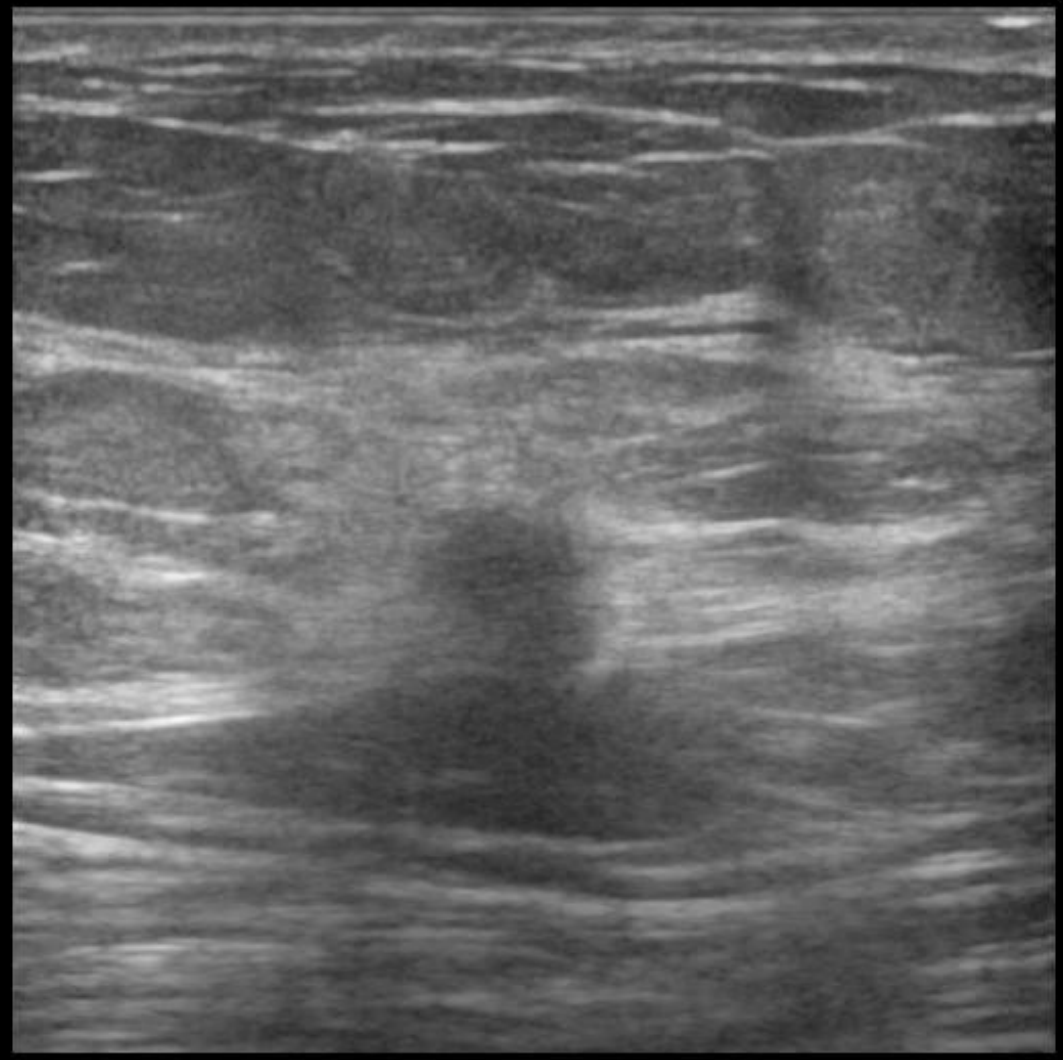
H

- 0

- 1

← - 2

- 3



FR:21
L75

BG:12 DR:70
HdTHI-P

症例 4

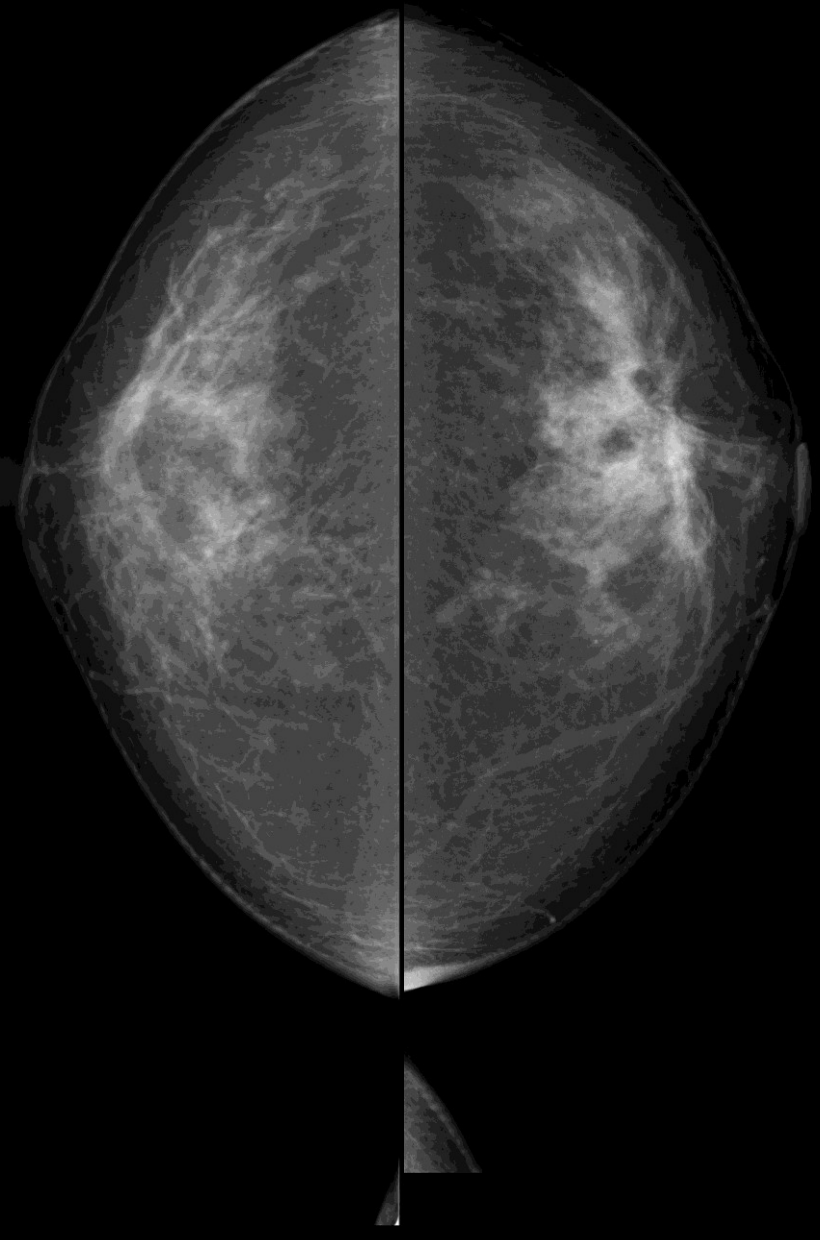
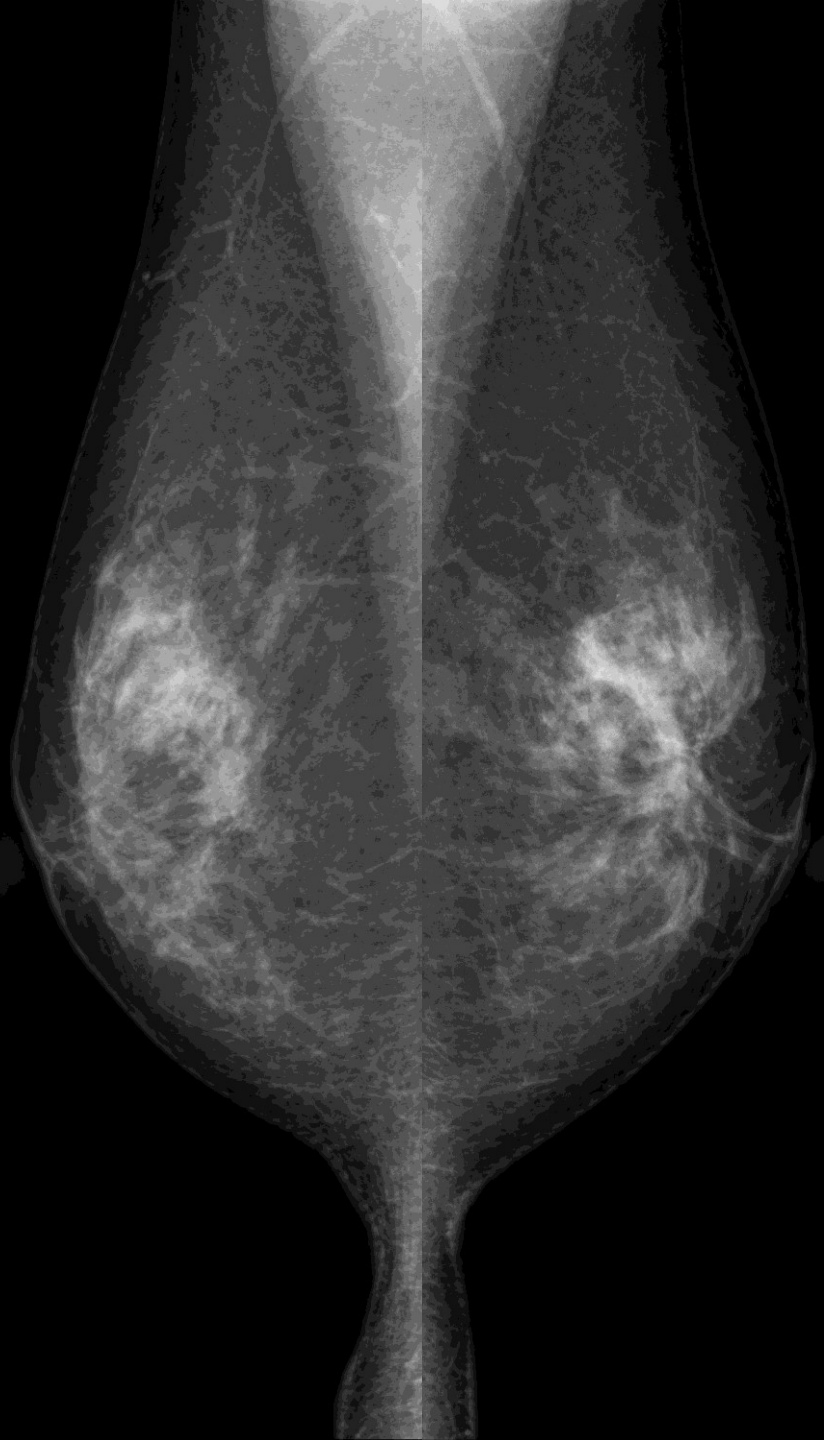
カテゴリー 1 / 4 5

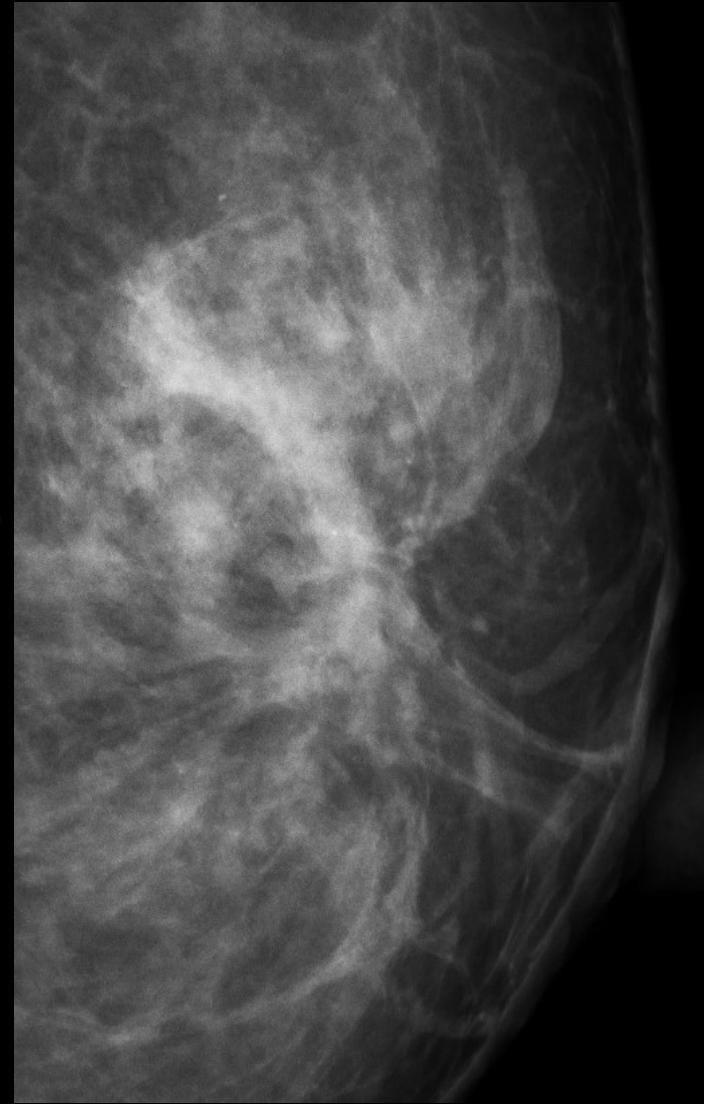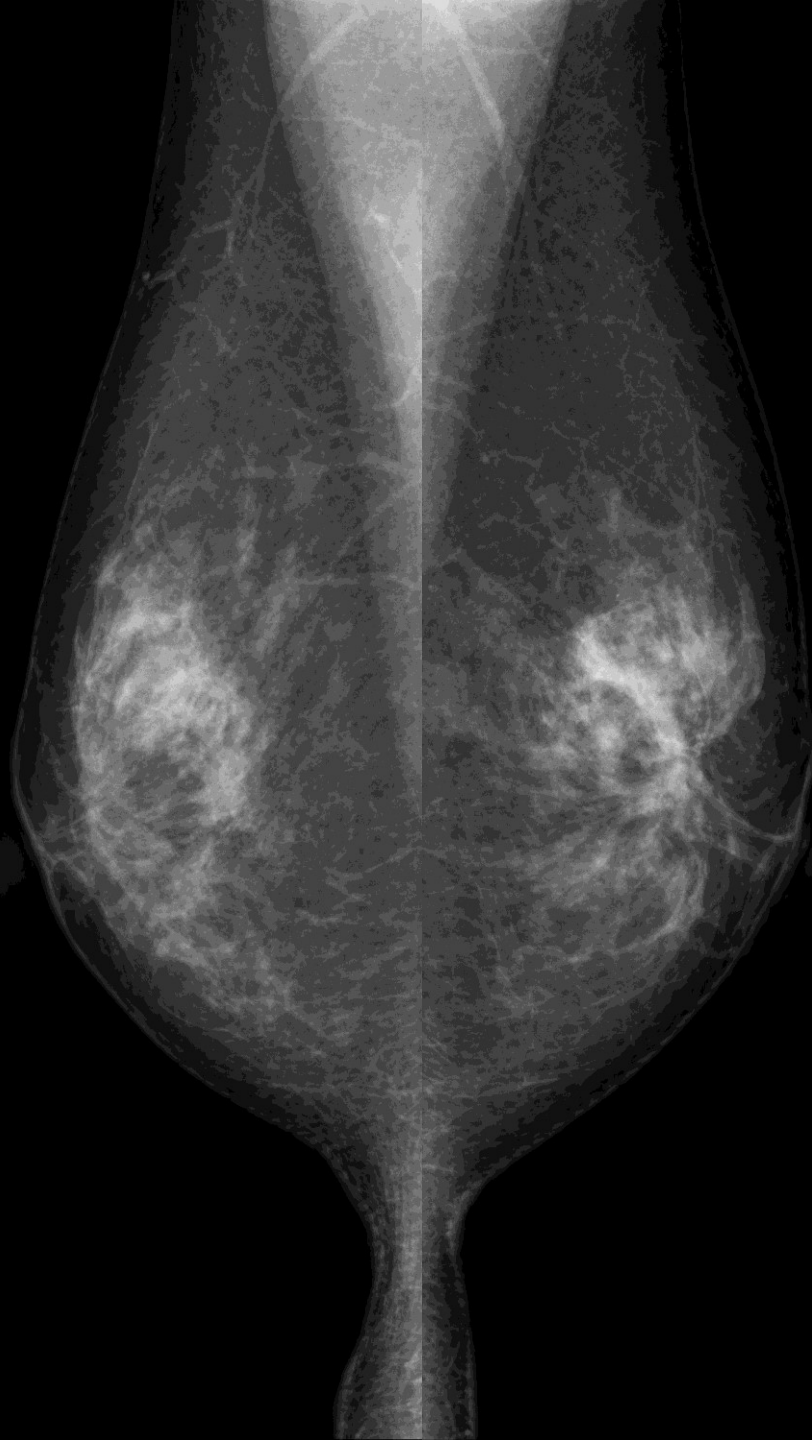
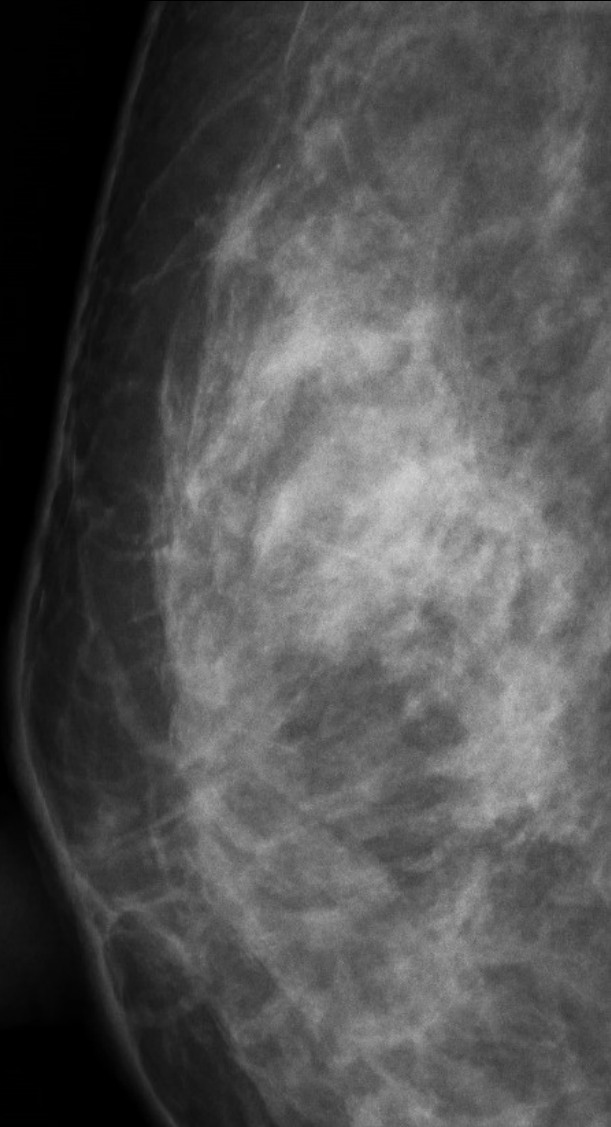
浸潤性乳管癌(硬性型)

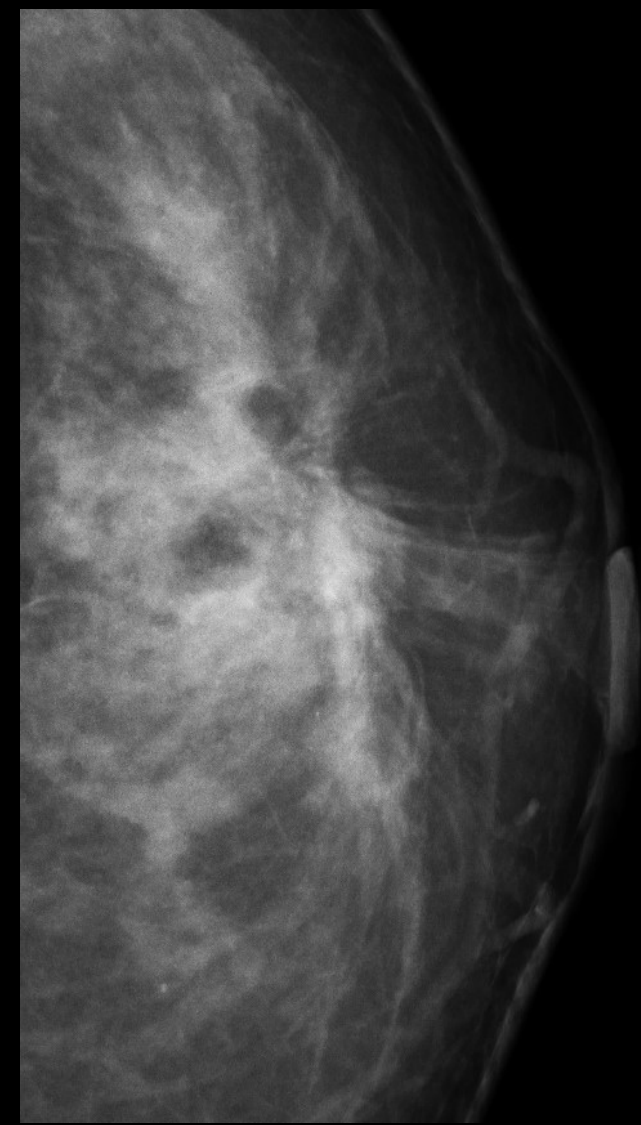
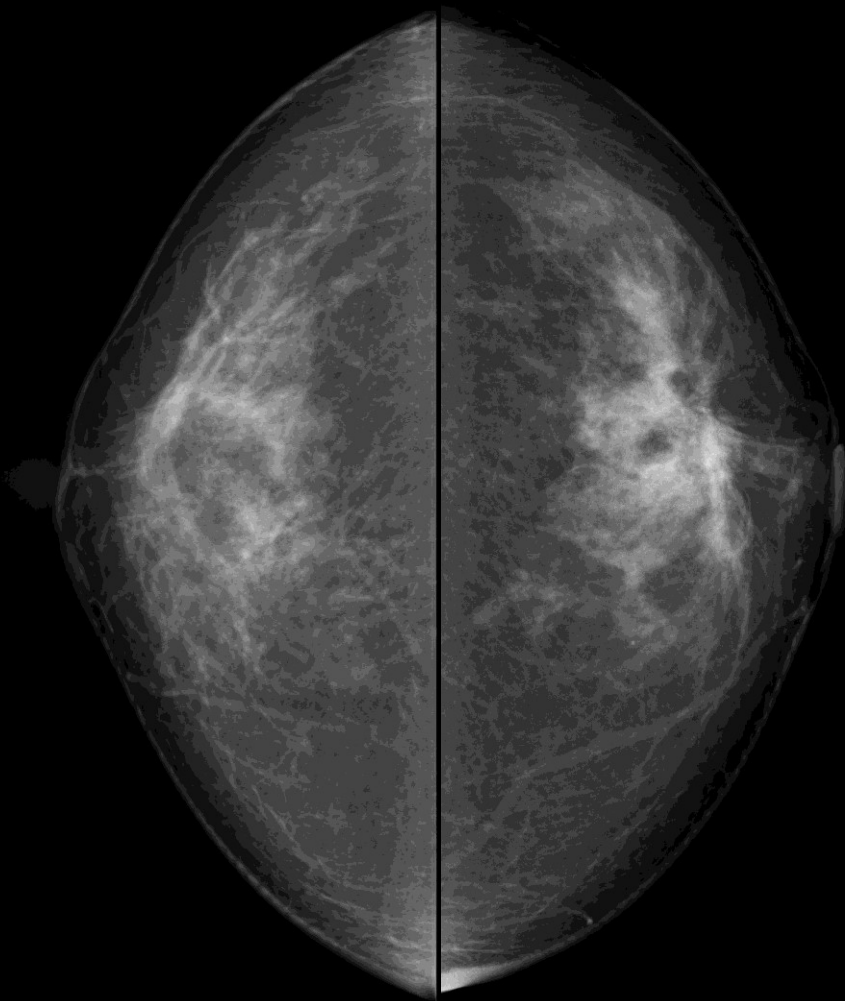
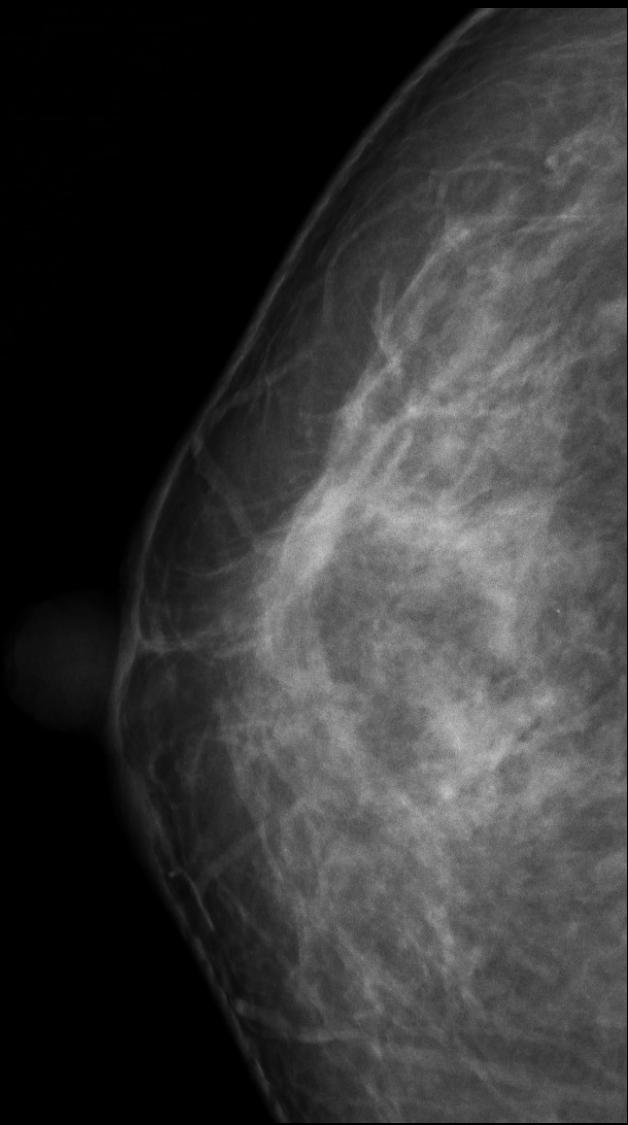T1cN0M0

症例 5

50歳 乳腺散在





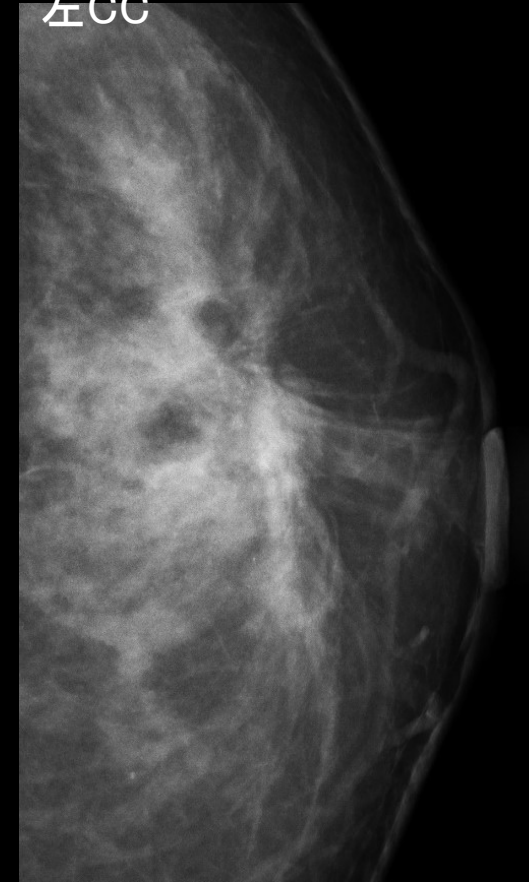
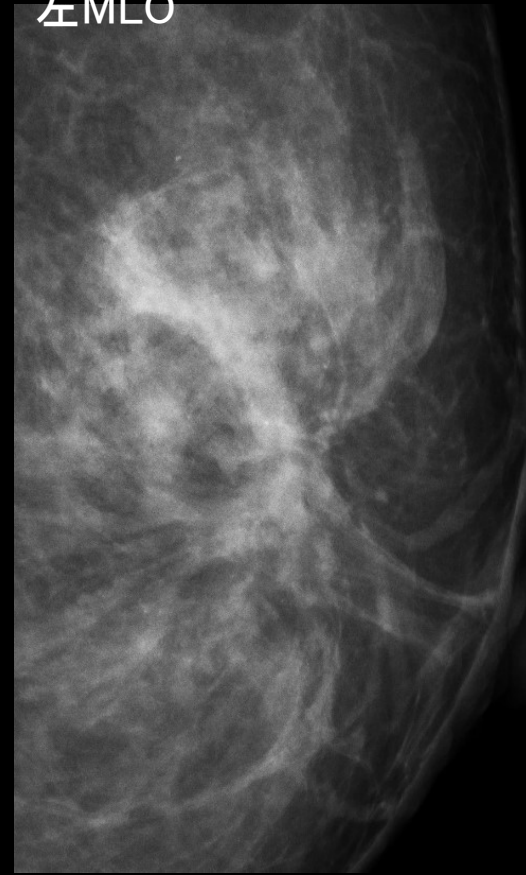
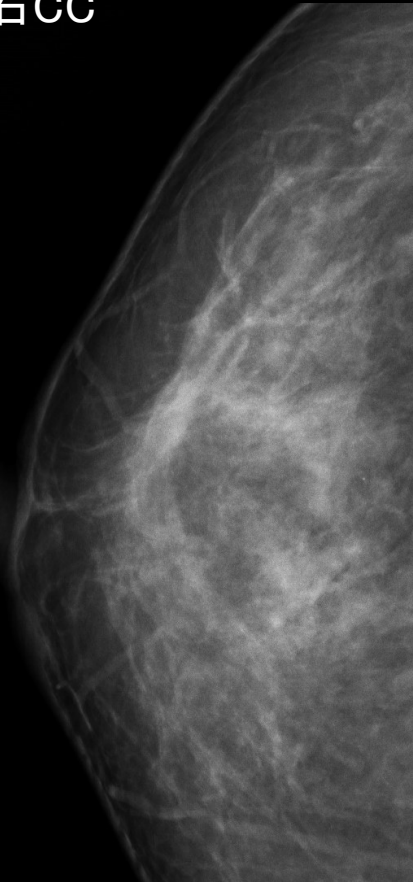
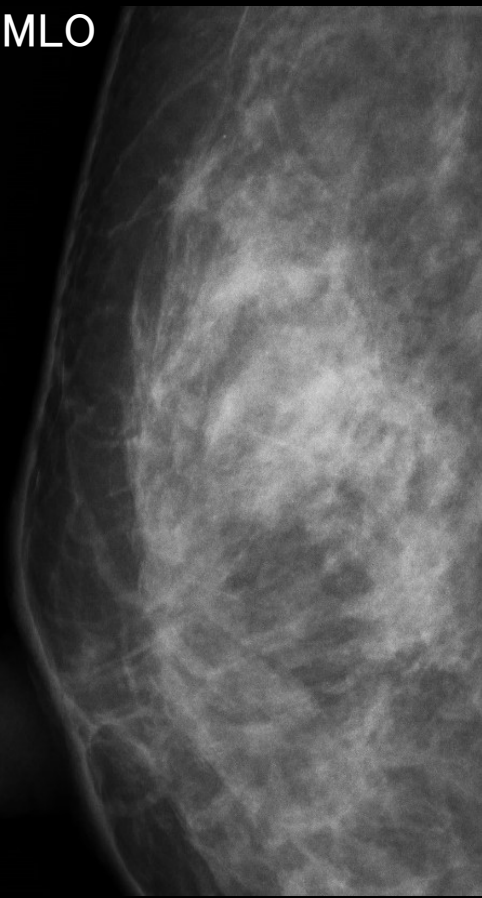


右MLO

右CC

左MLO

左CC



右 構築の乱れ疑い

左 構築の乱れ

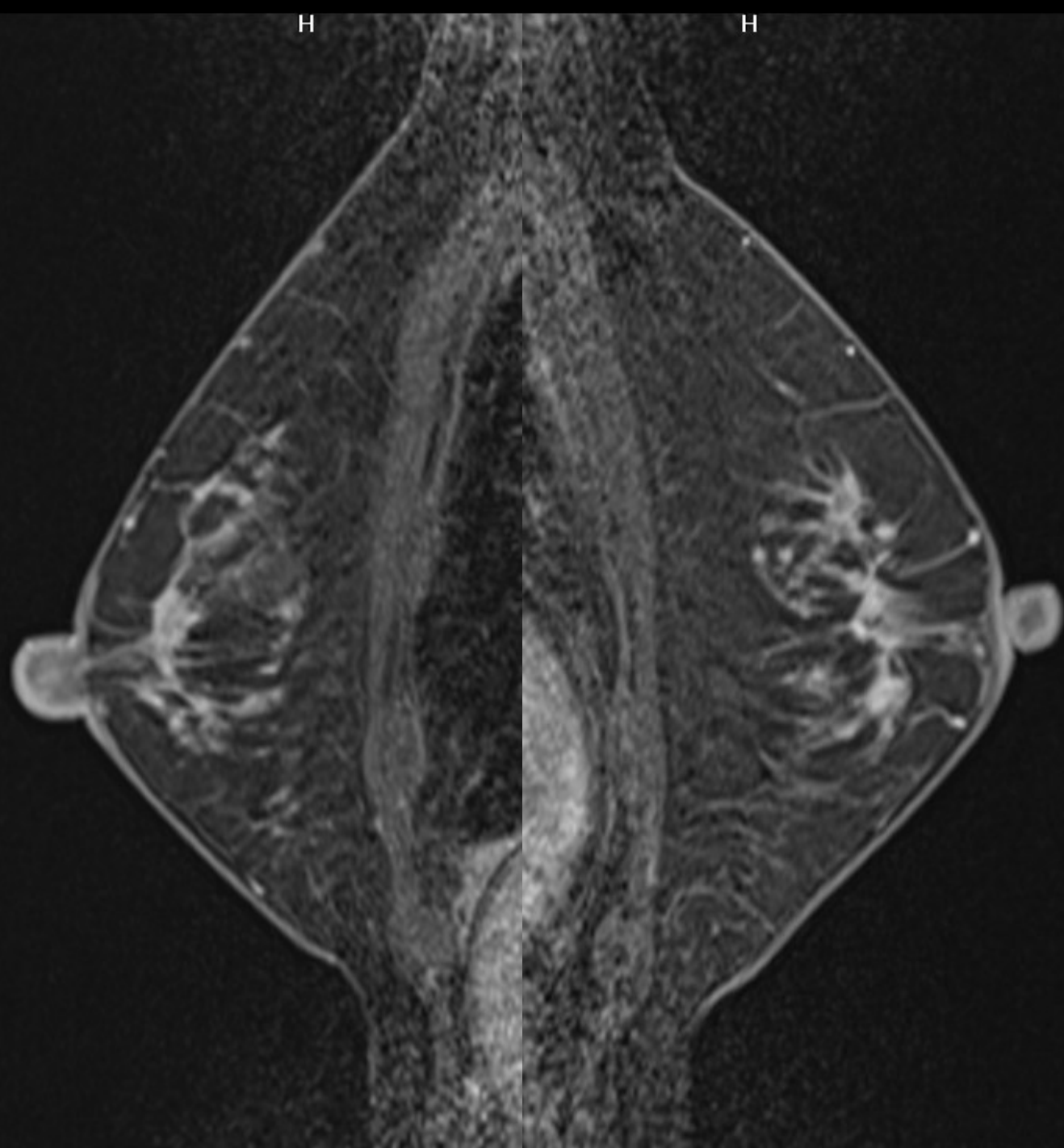
両側に少数の淡く不明瞭な石灰化を認める

右 カテゴリー 3(4)

左 カテゴリー 4

H


H



症例 5

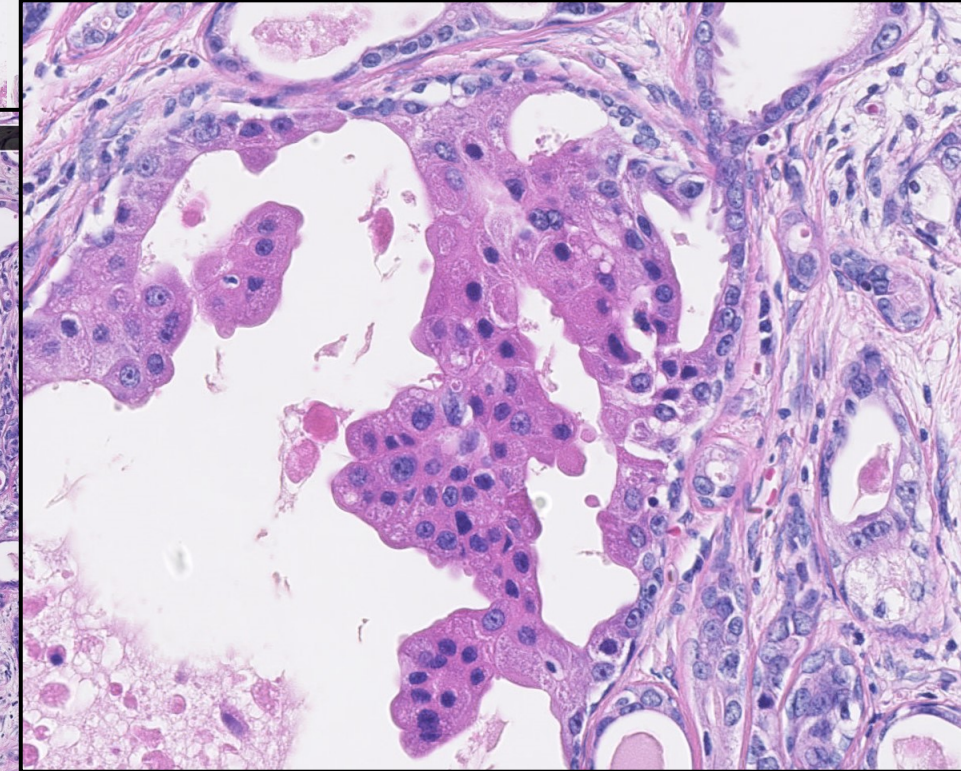
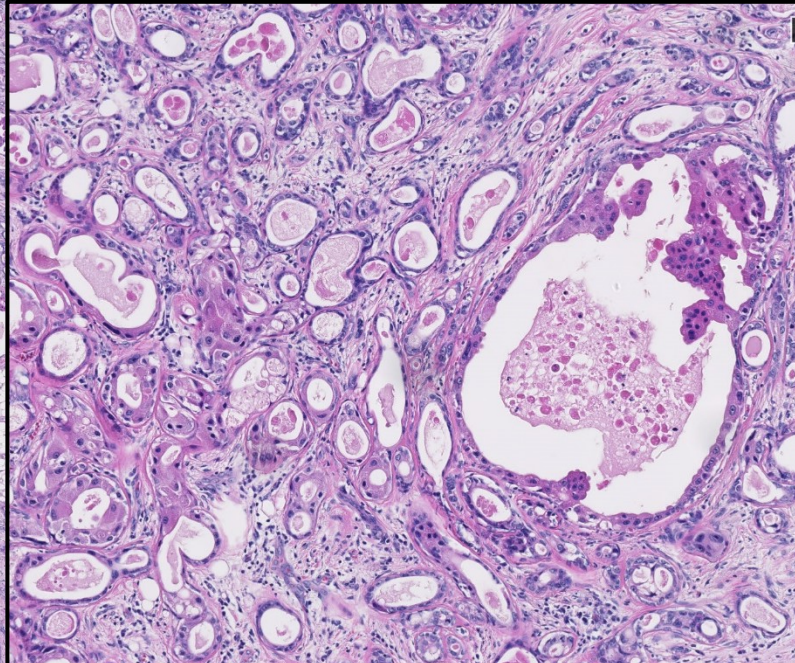
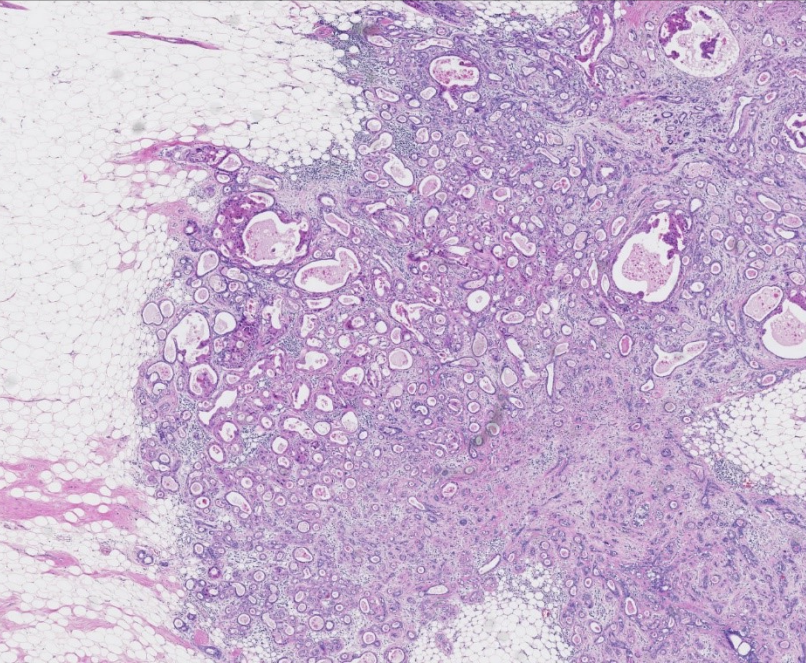
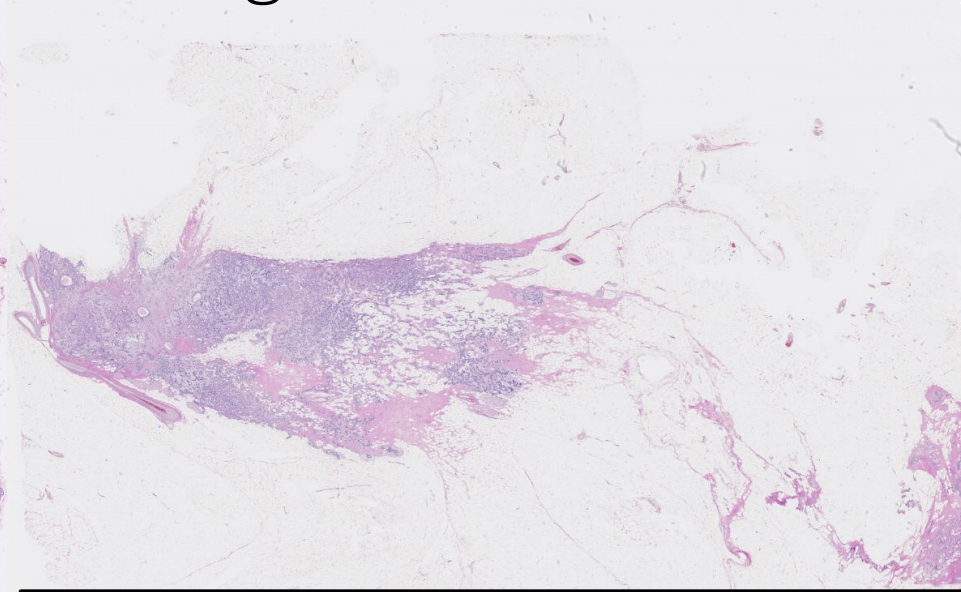
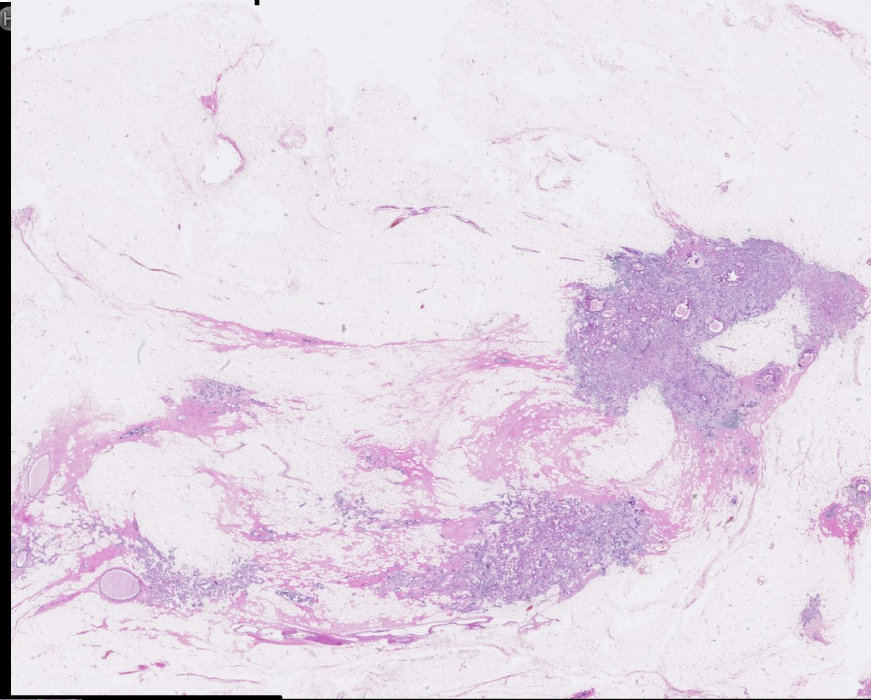
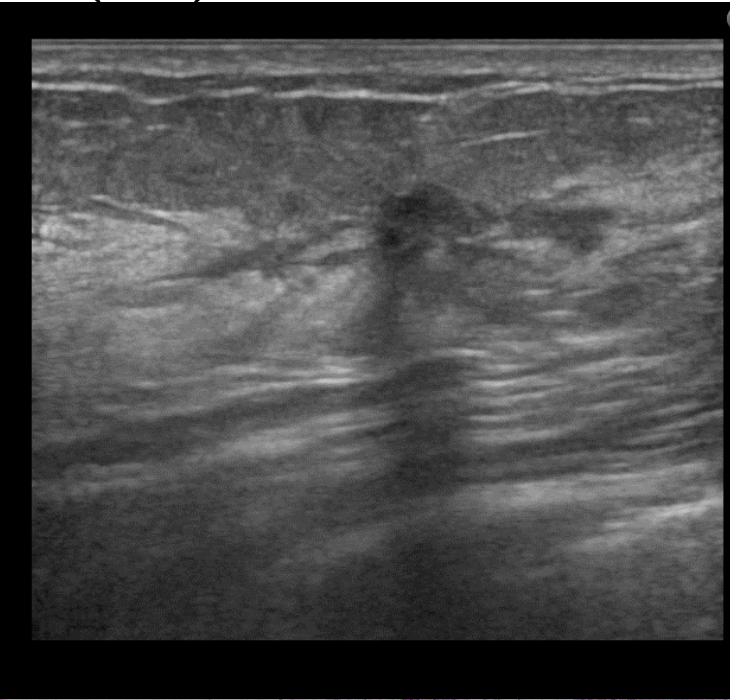
カテゴリー 3 (4) / 4

病理解説



(右)

Apocrine DCIS in sclerosing adenosis



(右)

1. Noninvasive ductal carcinoma in sclerosing adenosis of right breast, E area*, mastectomy

* Apocrine DCIS, 9X7X5mm, 断端(-)

2. Fibrocystic disease of right breast, marked

(左)

1. Apocrine carcinoma with a predominant intraductal components of left breast, E area*, mastectomy

* pT1c: 11x5mm (広がり: 45x10mm)

f, Ly0, V0, Nuclear grade: 3, Histological grade III,

2. One sentinel lymph node, negative for metastatic carcinoma, excised

3. Fibrocystic change of left breast, marked

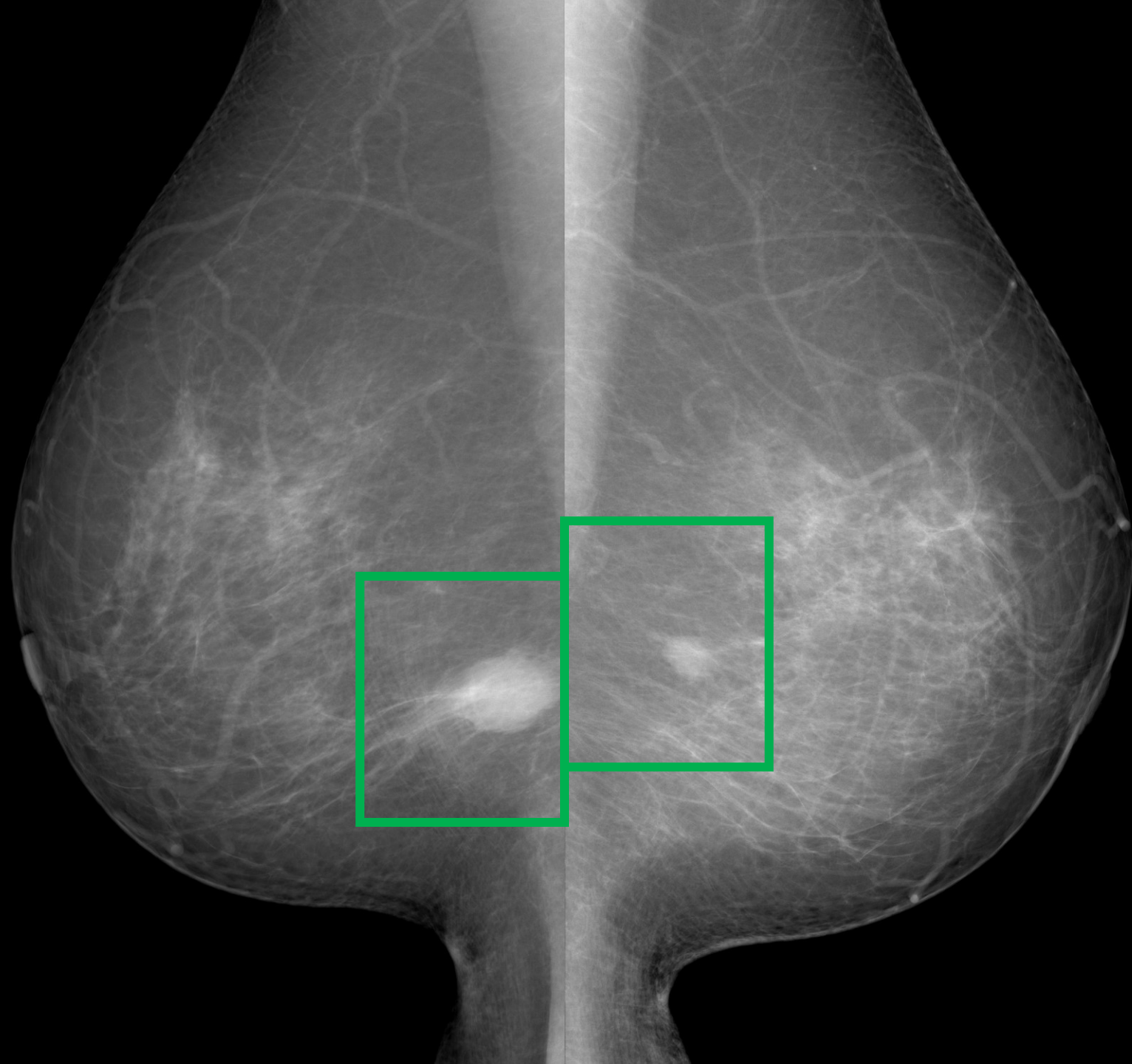
症例 6

カテゴリー 1 / 1

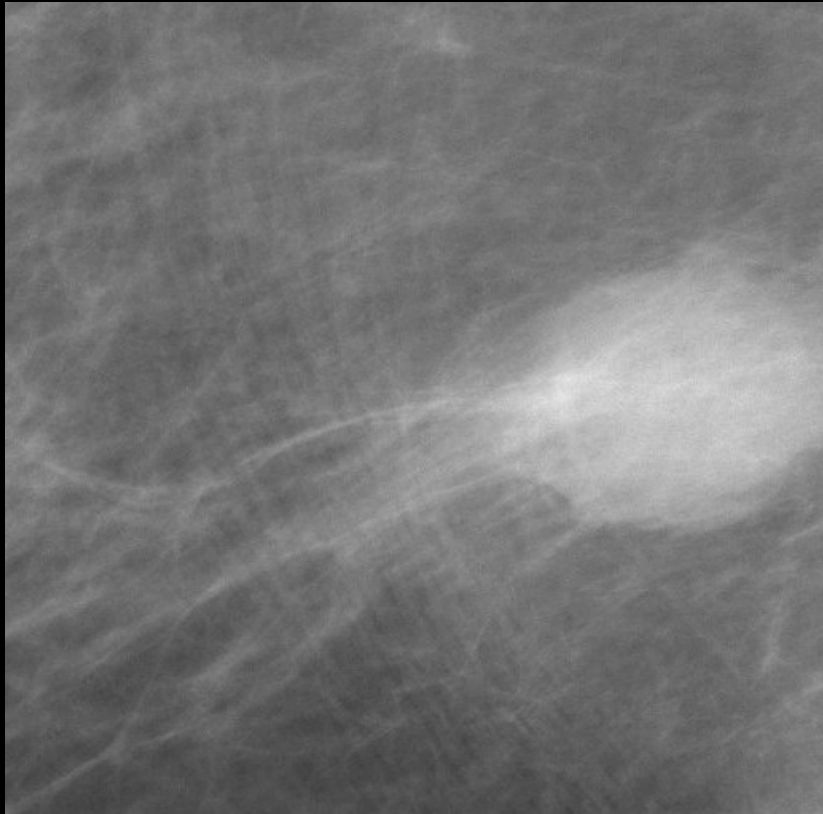
正常

症例 7

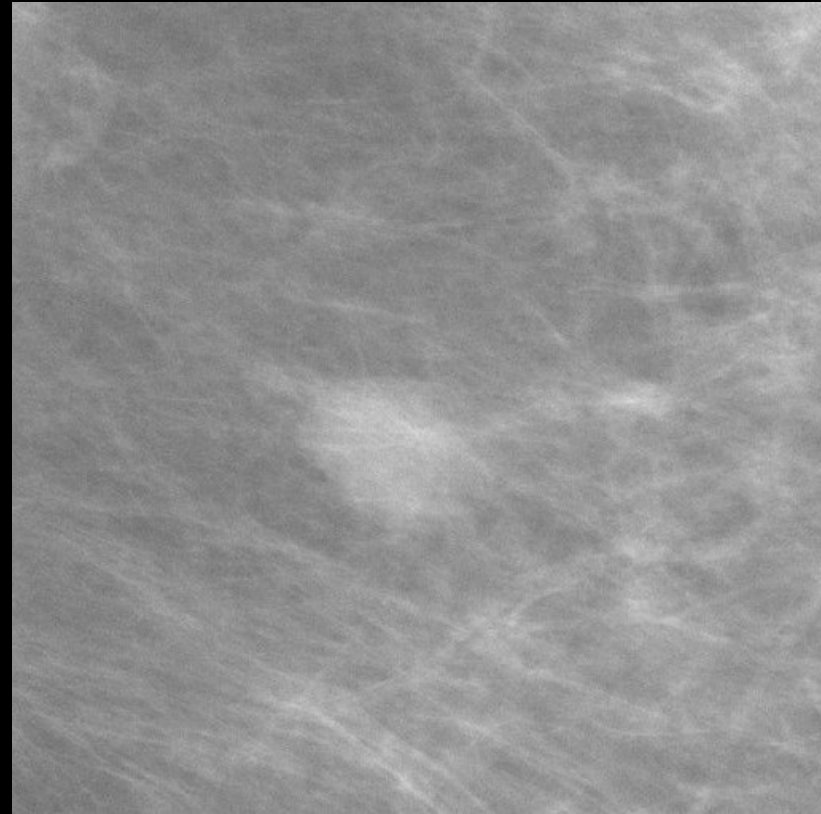
74歳 乳腺散在



右MLO



左MLO

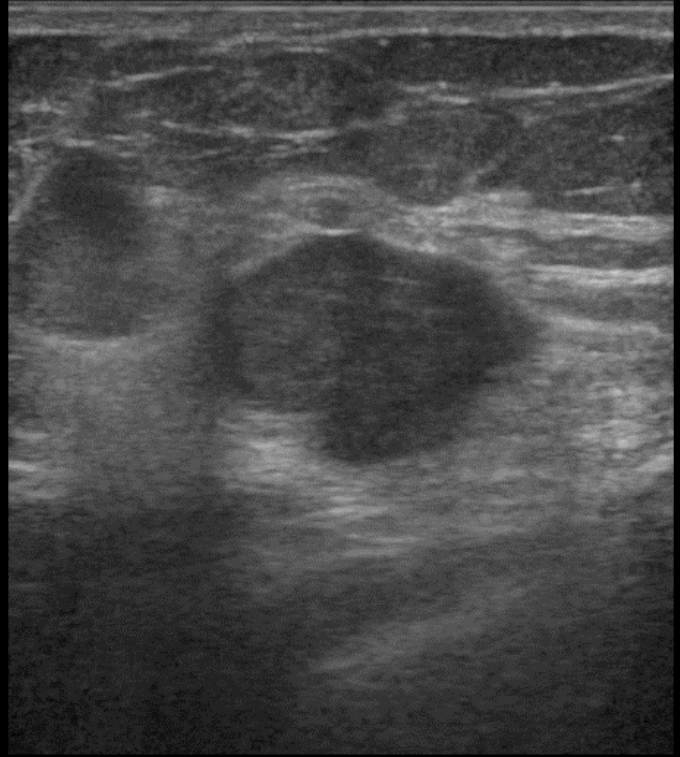

右 境界不明瞭な高濃度の円形腫瘍

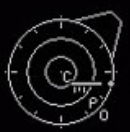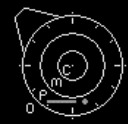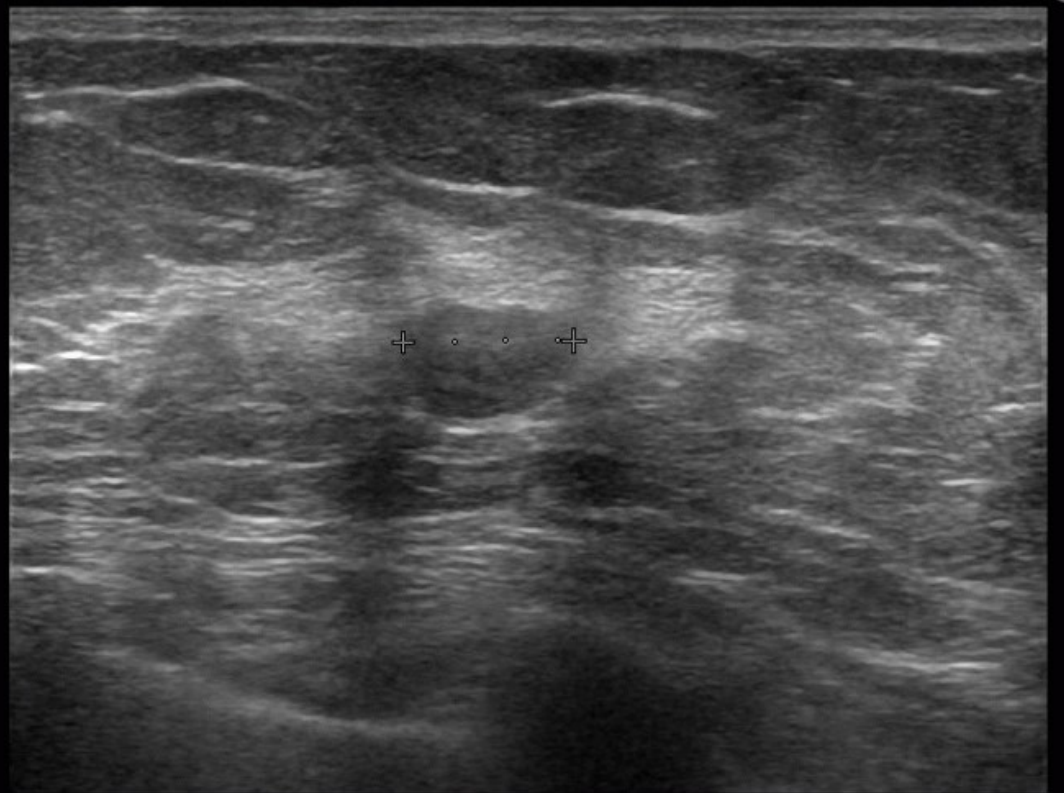
左 境界明瞭平滑、一部評価困難な等～やや高濃度の円形腫瘍

右 カテゴリー 4

左 カテゴリー 3(4)



- 0
-
- 1



FR:21
L75

BG:12 DR:70
HdTHI-P

Calip
+ D1 8.3 mm

FR:26
L74M

BG:7 DR:70
HdTHI-R

症例 7

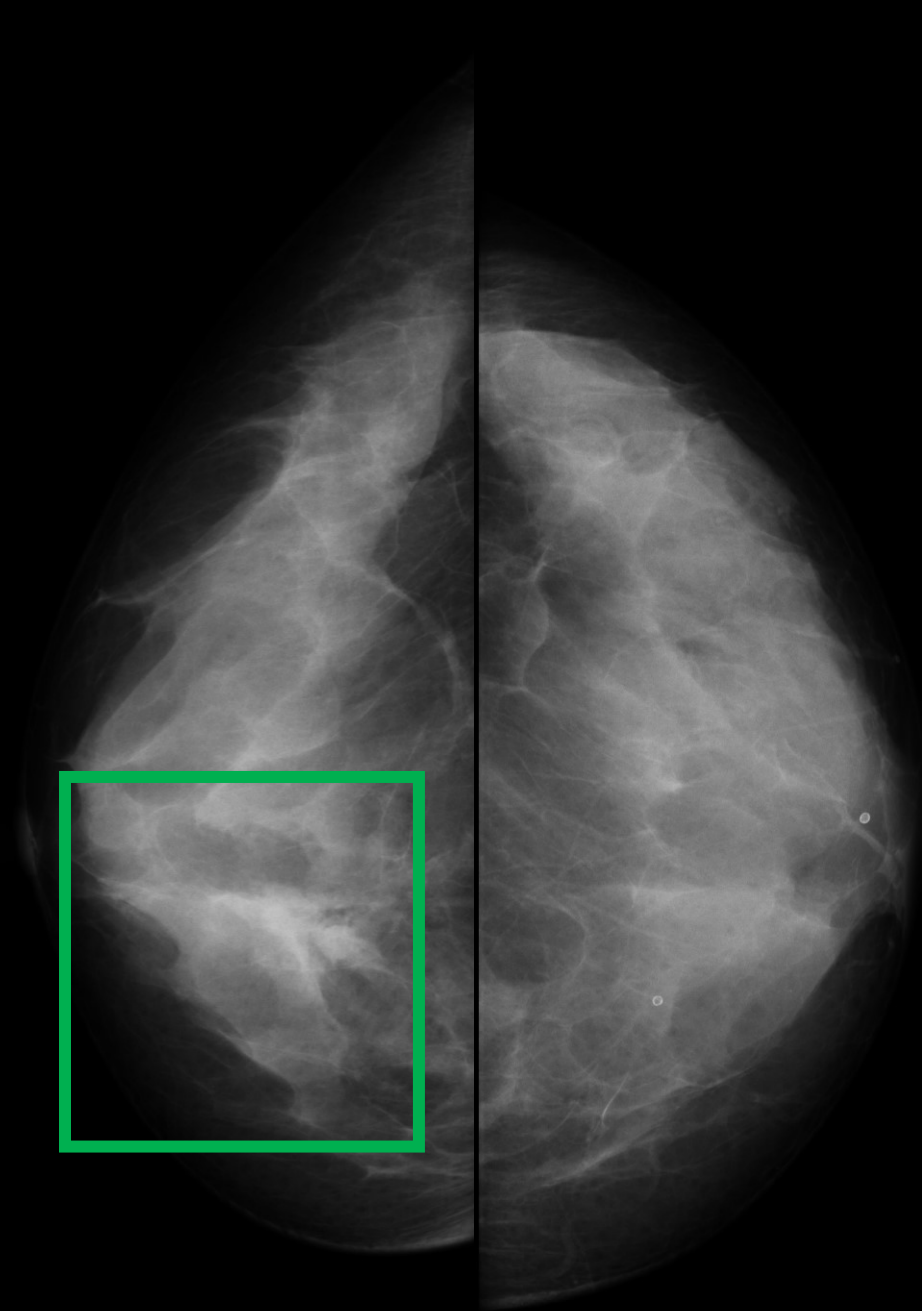
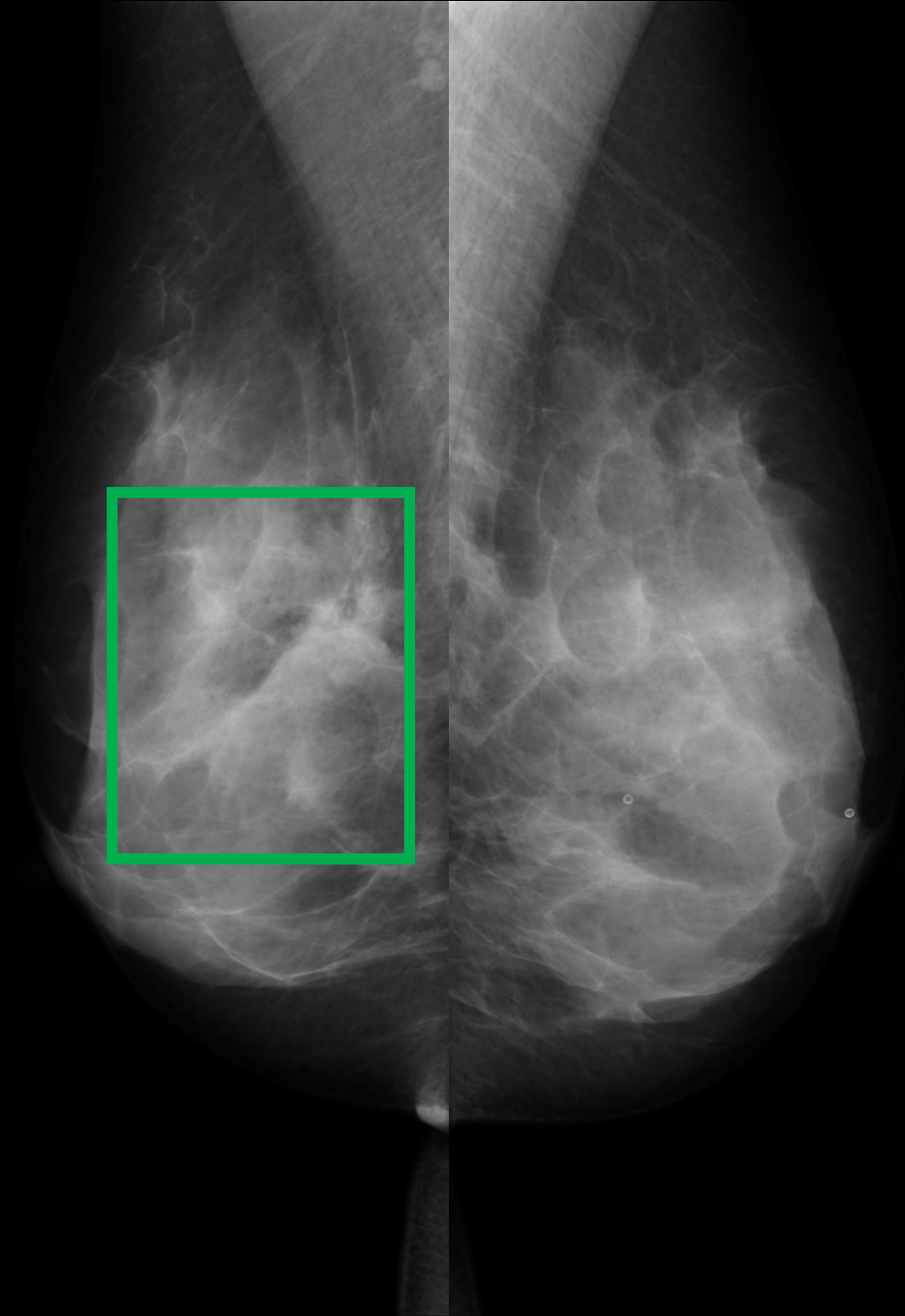
カテゴリー 4 / 3 (4)

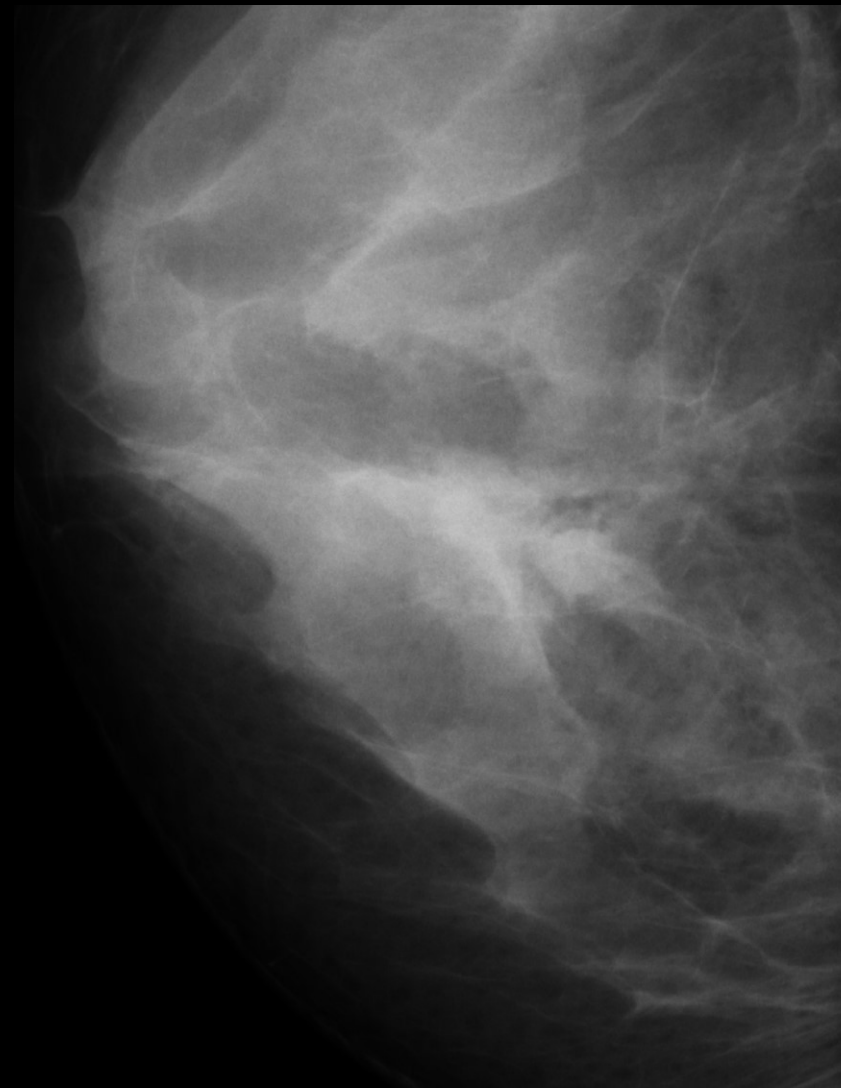
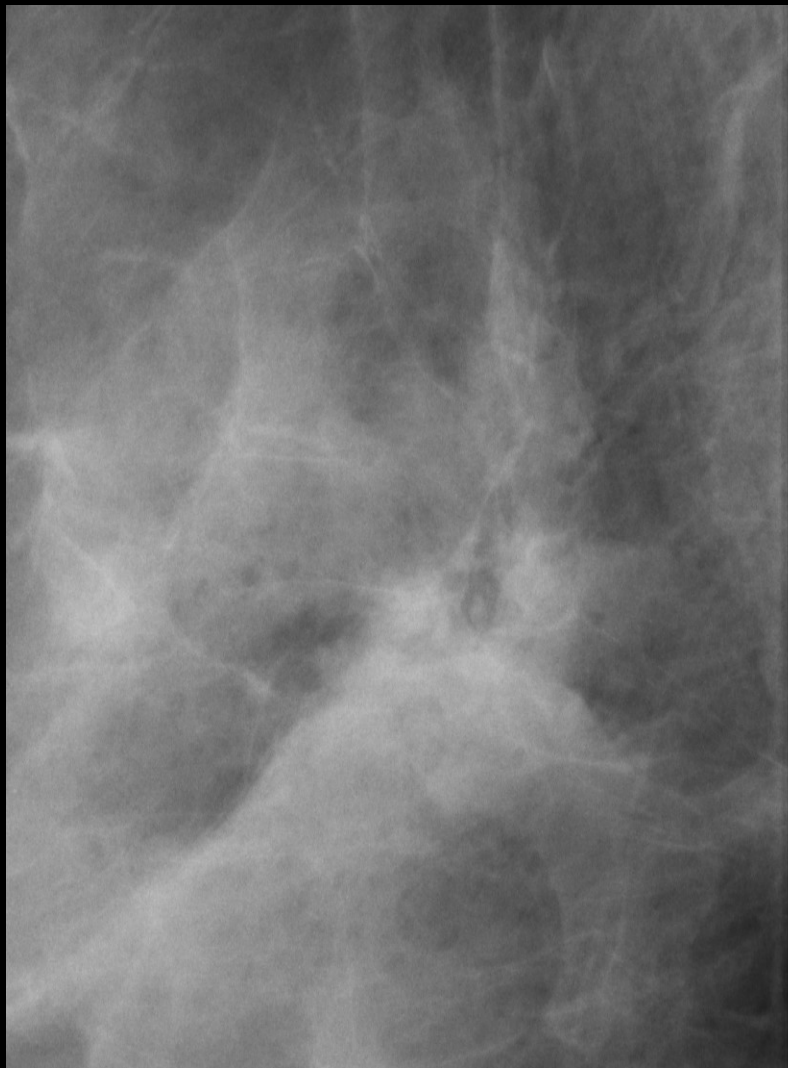右 浸潤性乳管癌(充実型)

左 嚢胞

症例 8

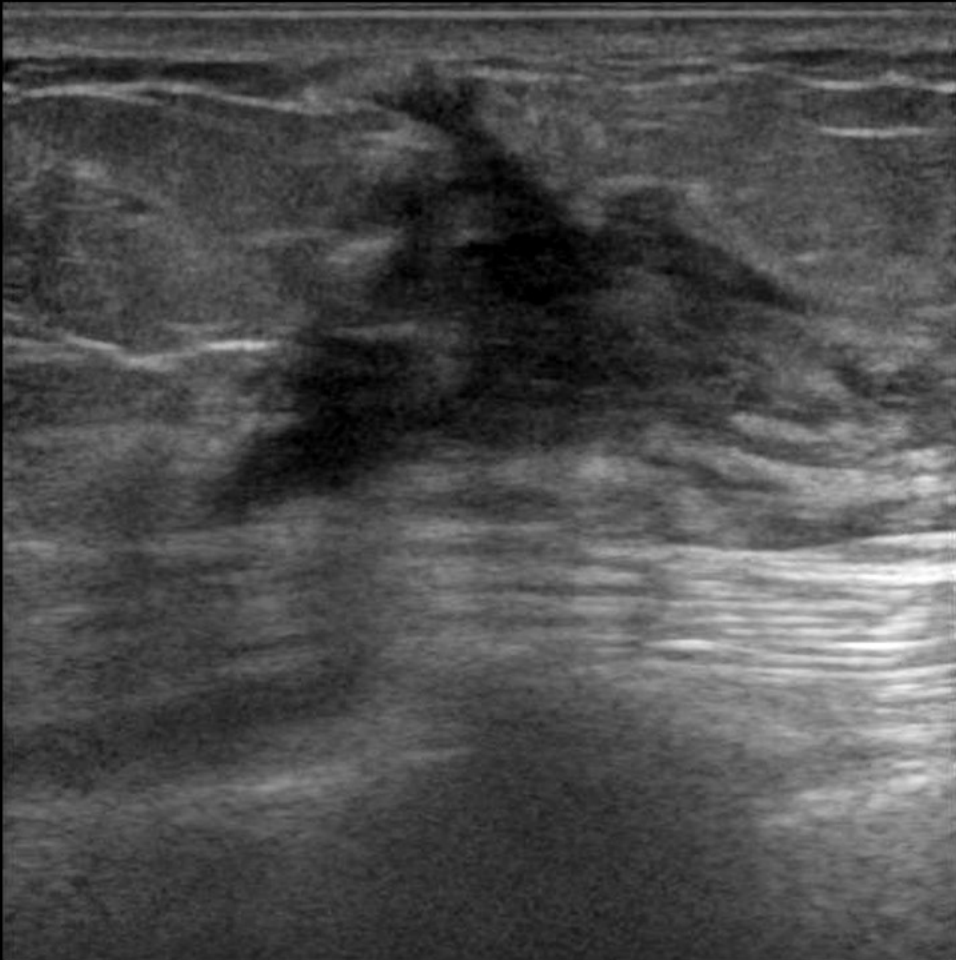
64歳 不均一高濃度



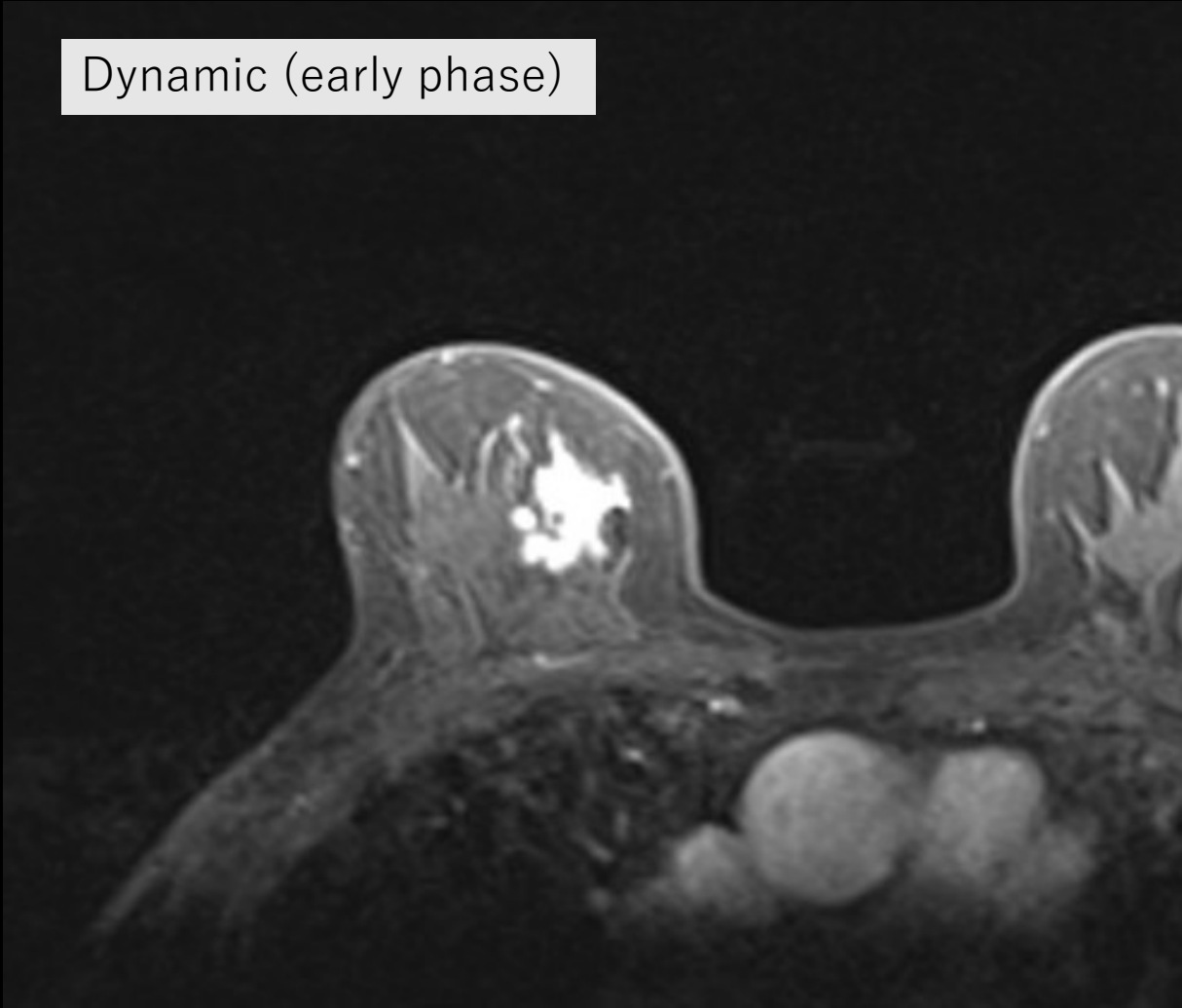


構築の乱れ、もしくはスピキュラを有する不整形のやや高濃度腫瘍

カテゴリー 4 5



Dynamic (early phase)

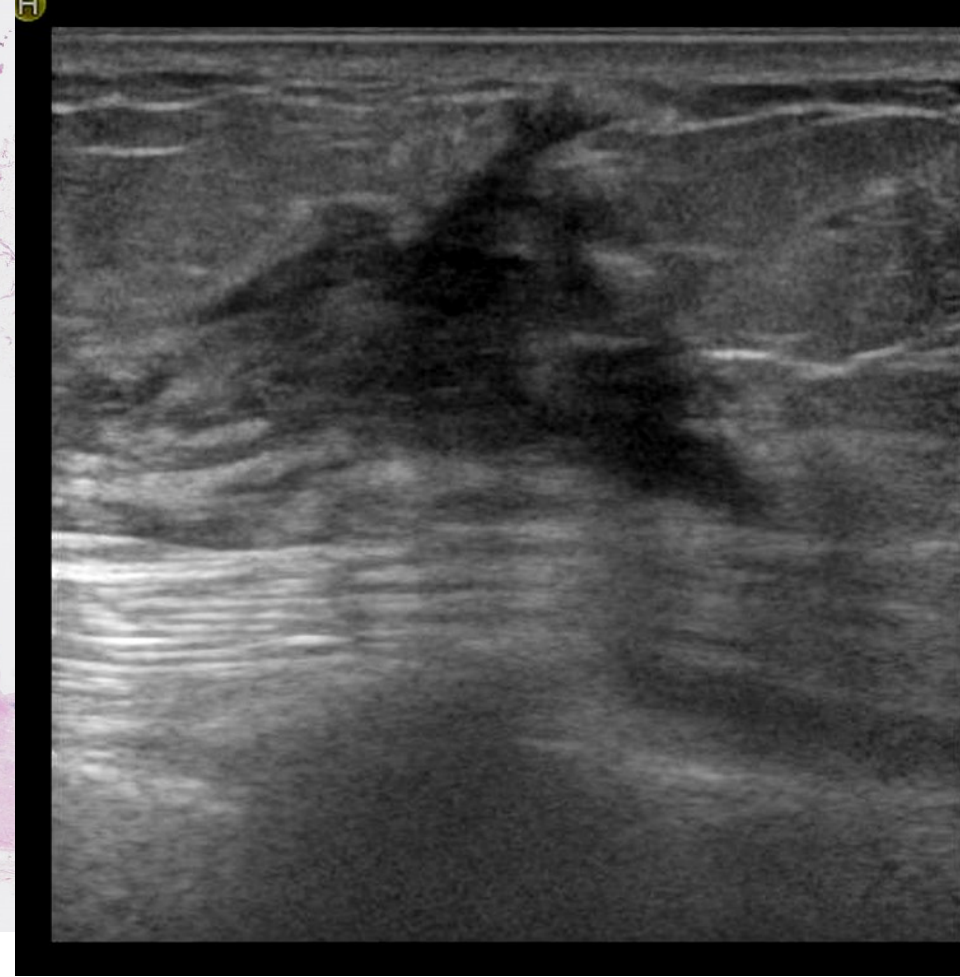
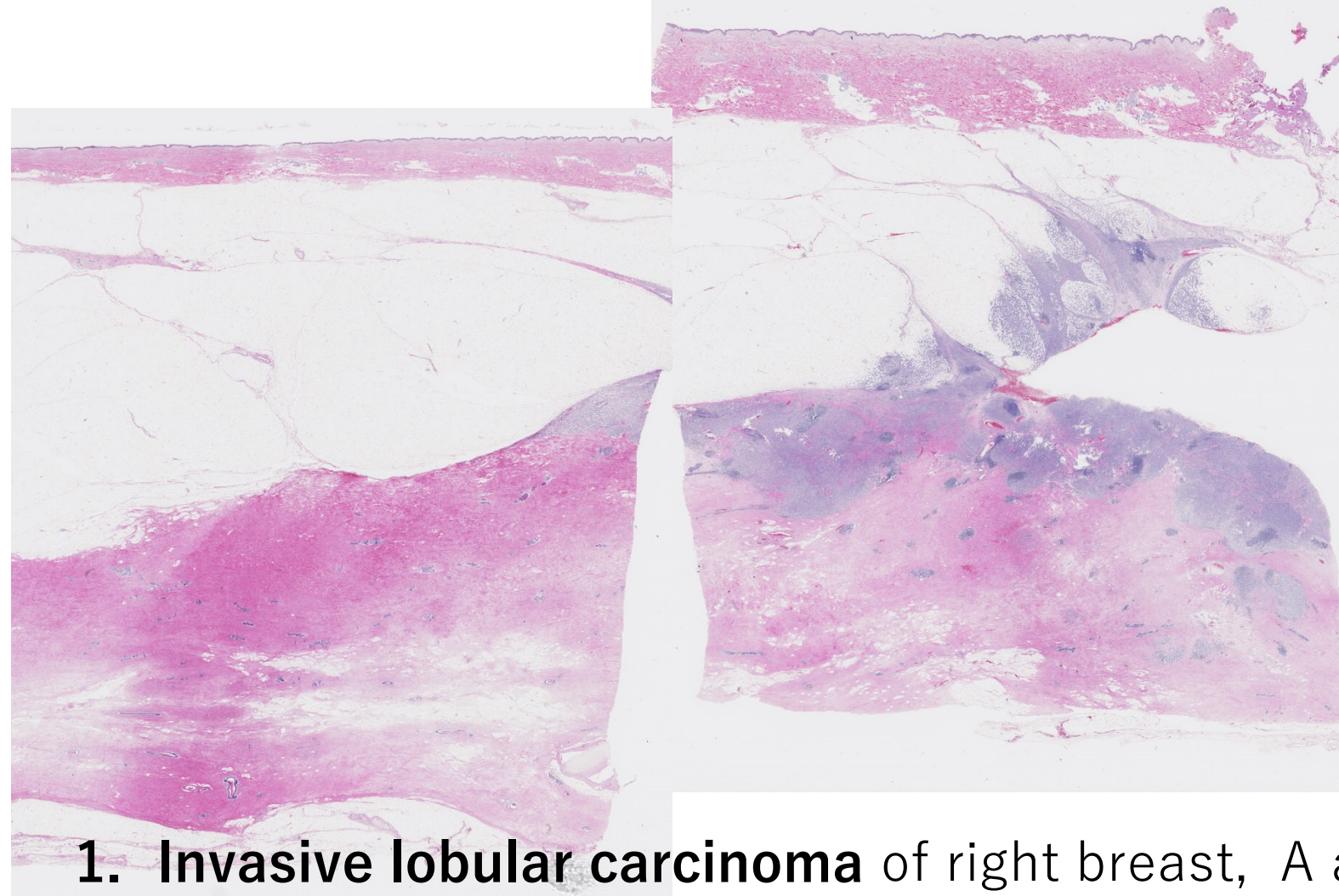


症例 8

カテゴリー 4 5 / 1

病理解説





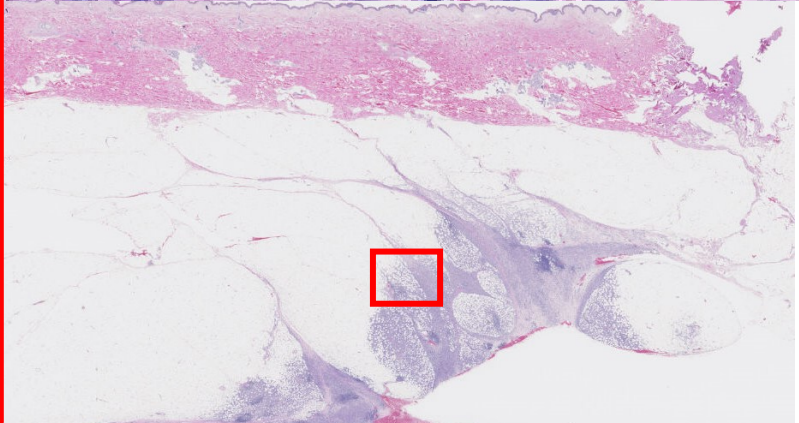
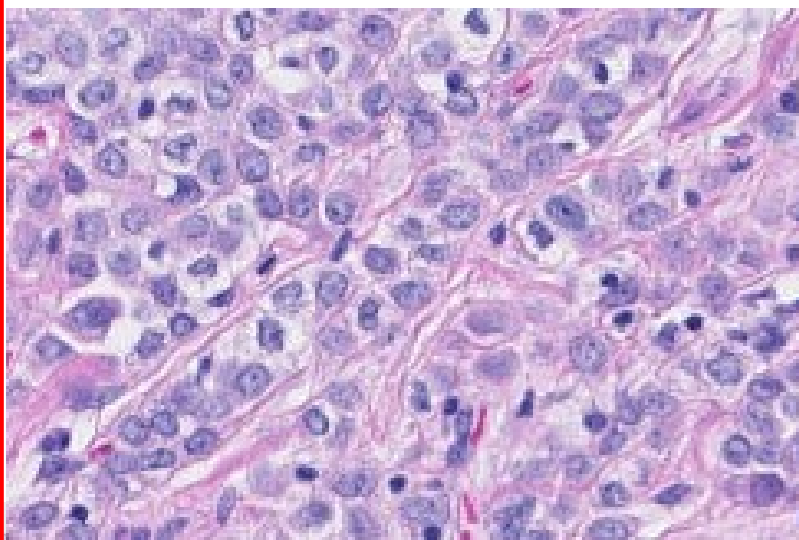
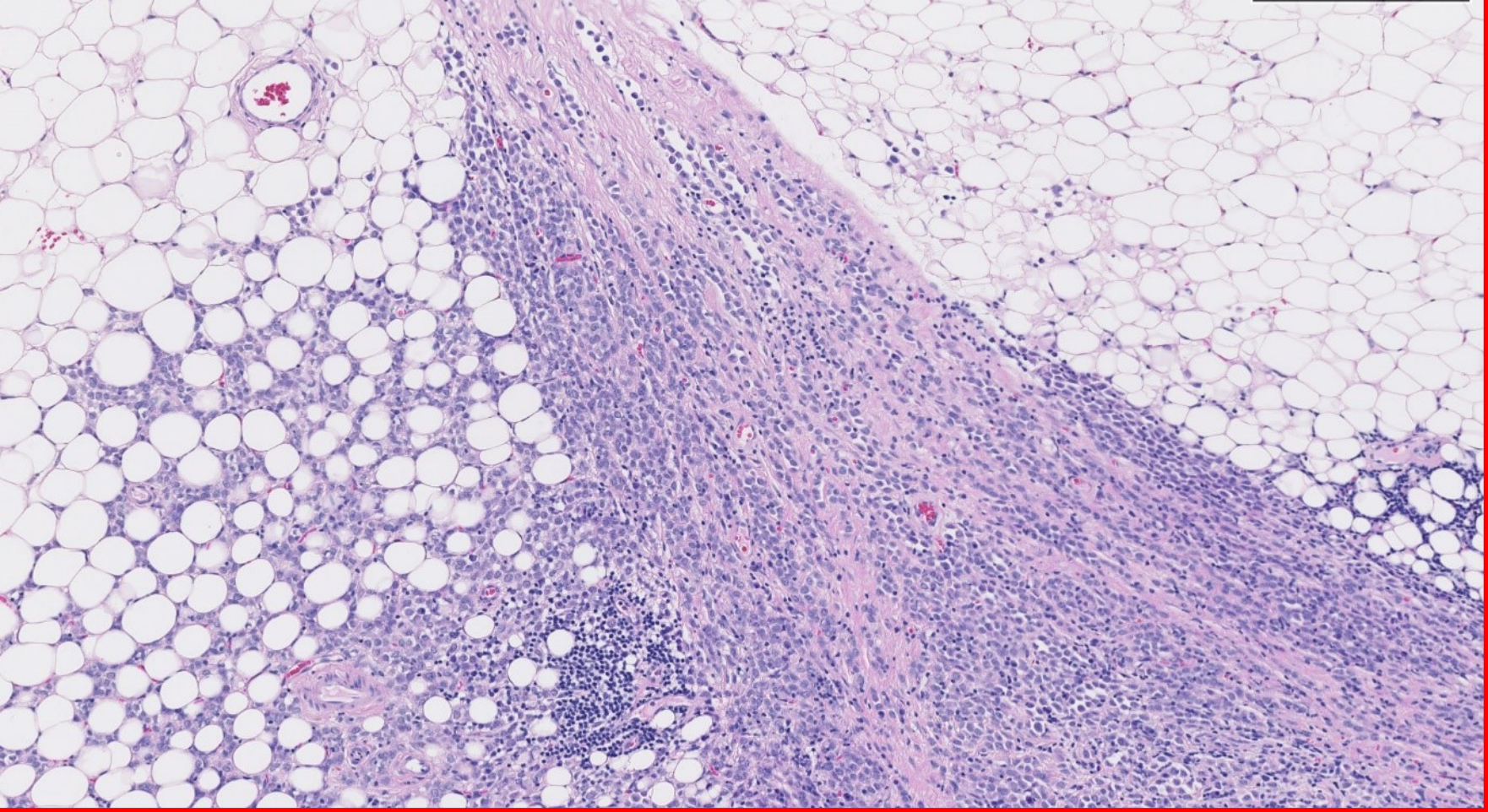
1. **Invasive lobular carcinoma** of right breast, A area*, mastectomy

* pT2: 40x20x15mm, classic type, f, Ly0, V0, 断端(-)

Nuclear grade: 2, Histological grade II,

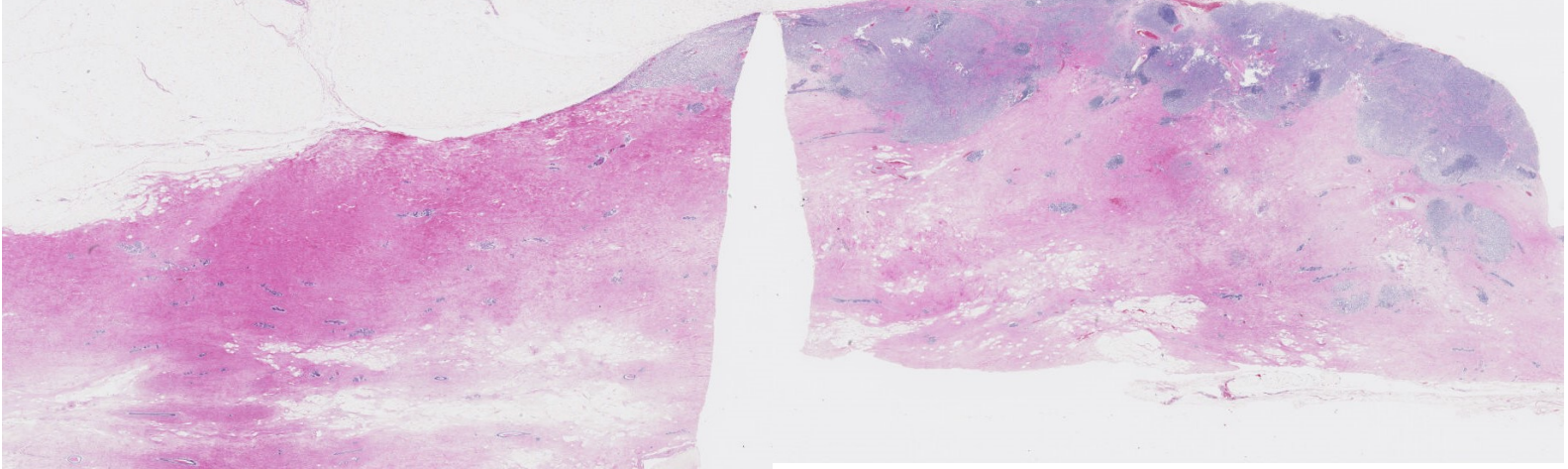
Intraductal spread (-), 娘結節(-)

2. Two sentinel lymph nodes, both negative for metastatic carcinoma, excised



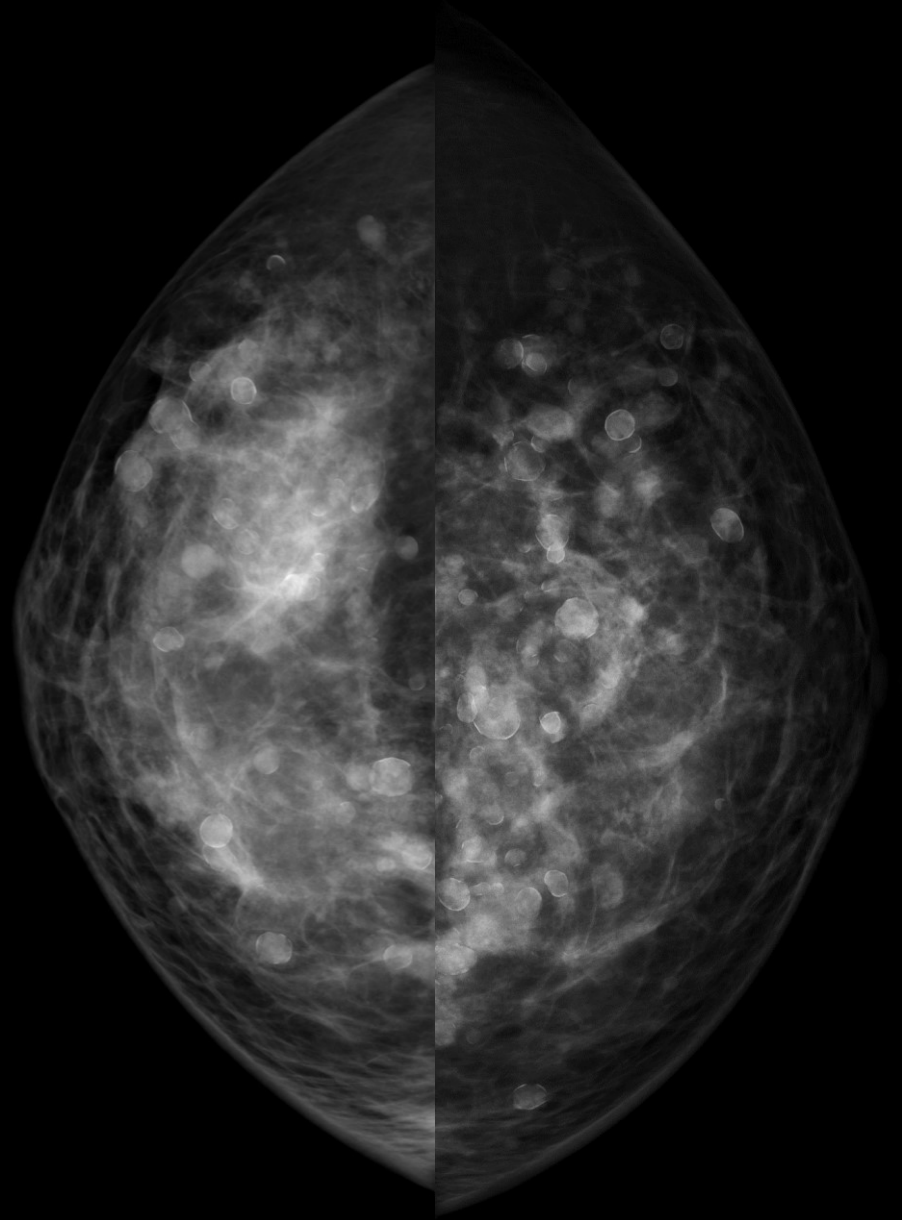
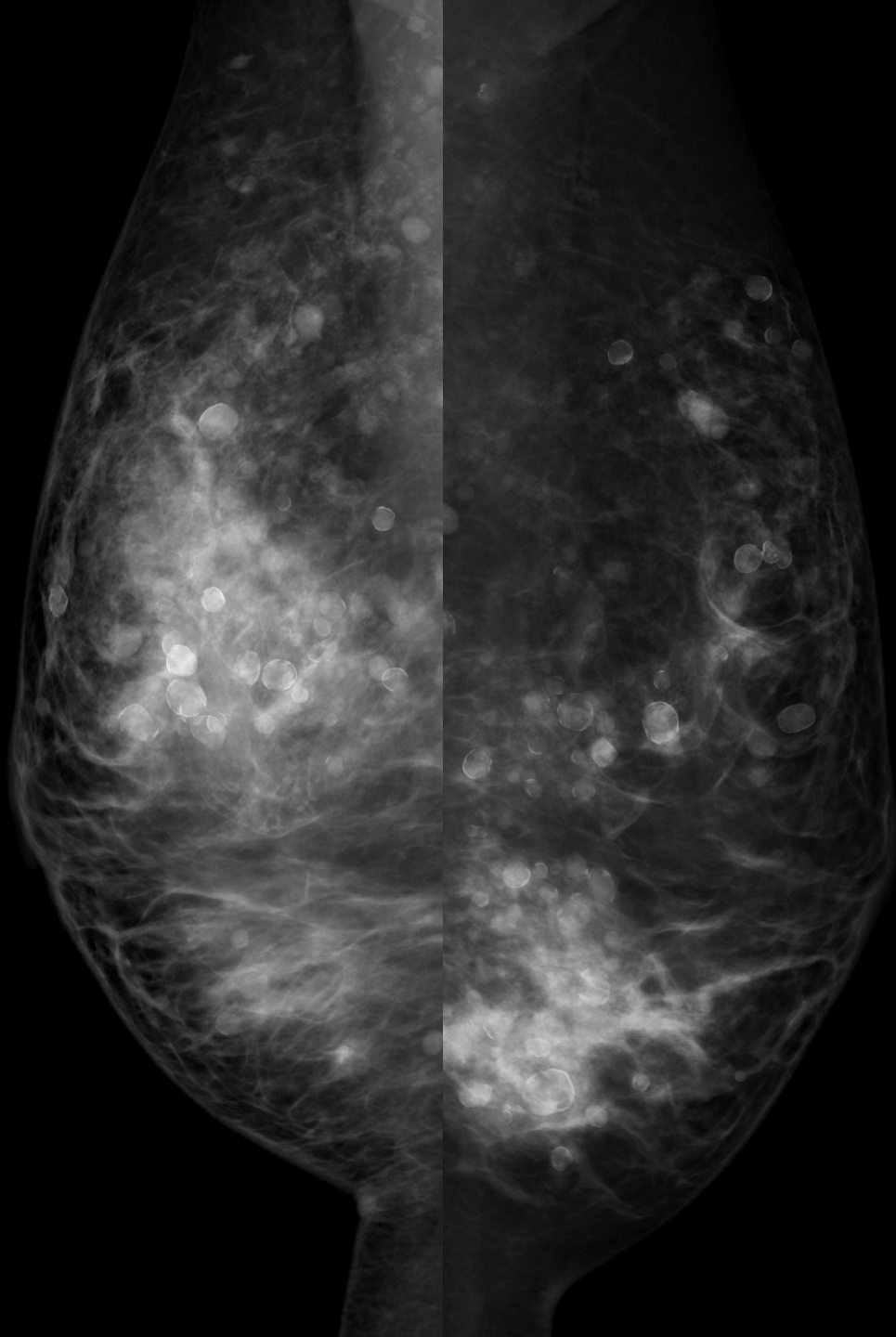
Invasive lobular carcinoma

T2N0M0



症例 9

58歳 乳腺散在



症例 9

カテゴリー 2 / 2

豊胸術後

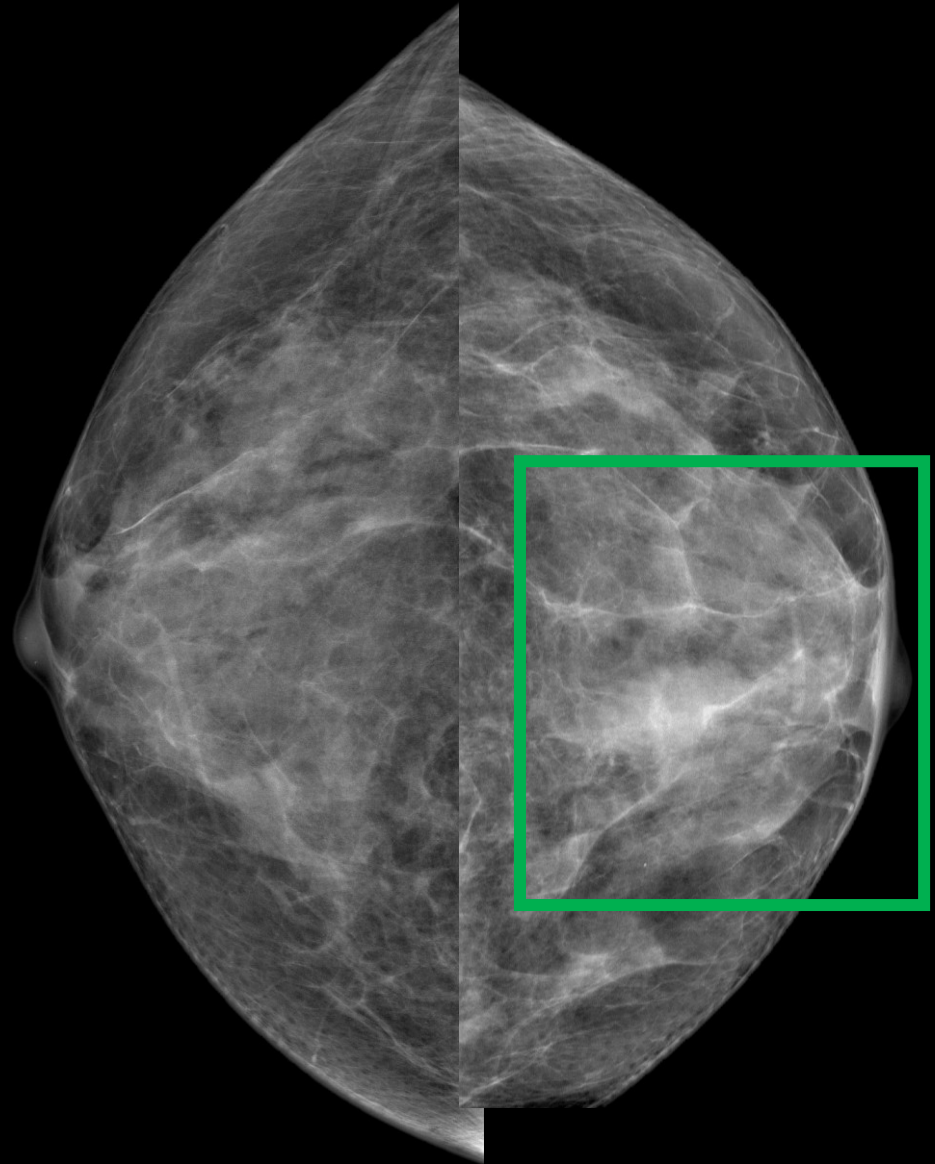
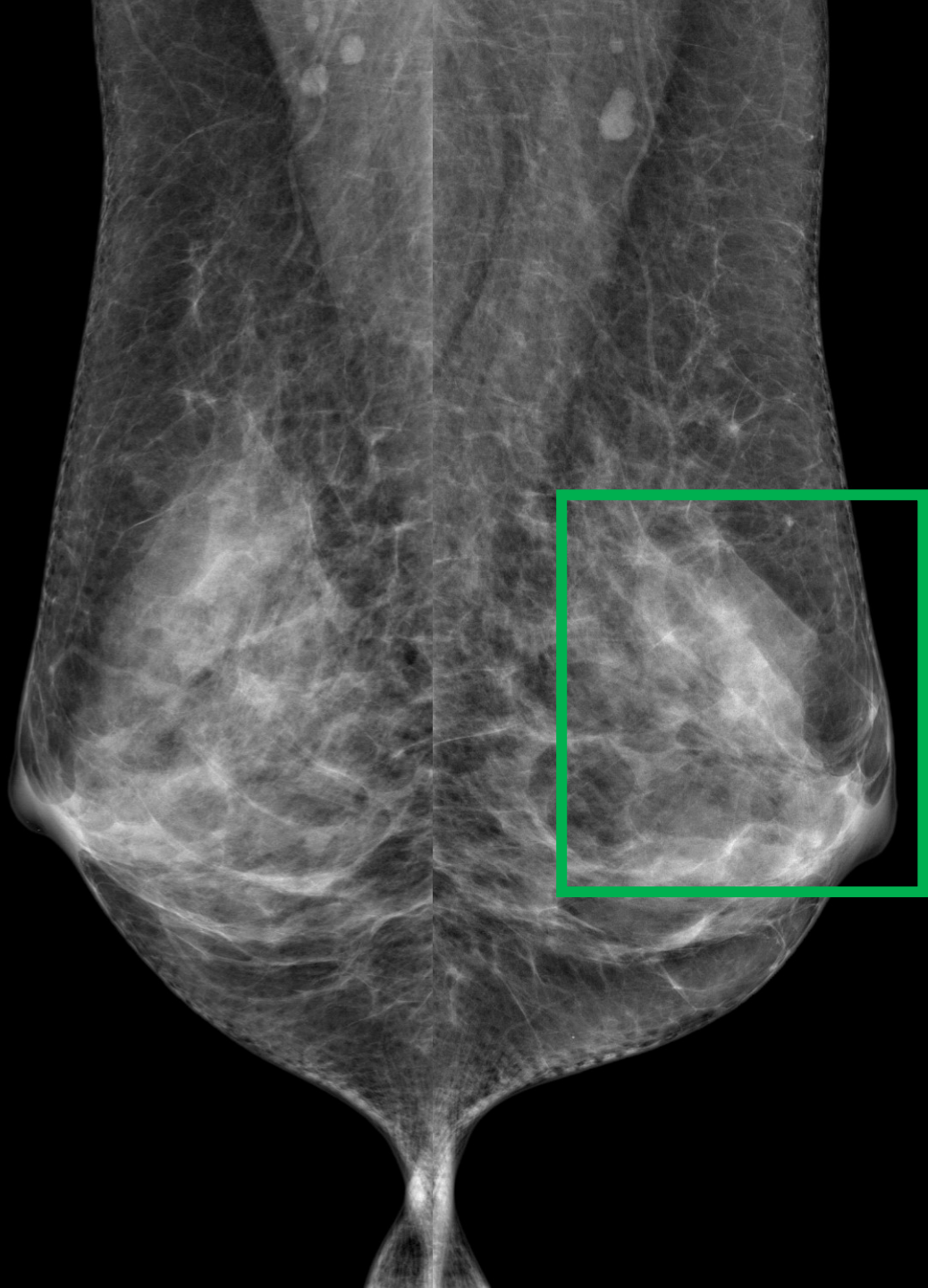
症例 10

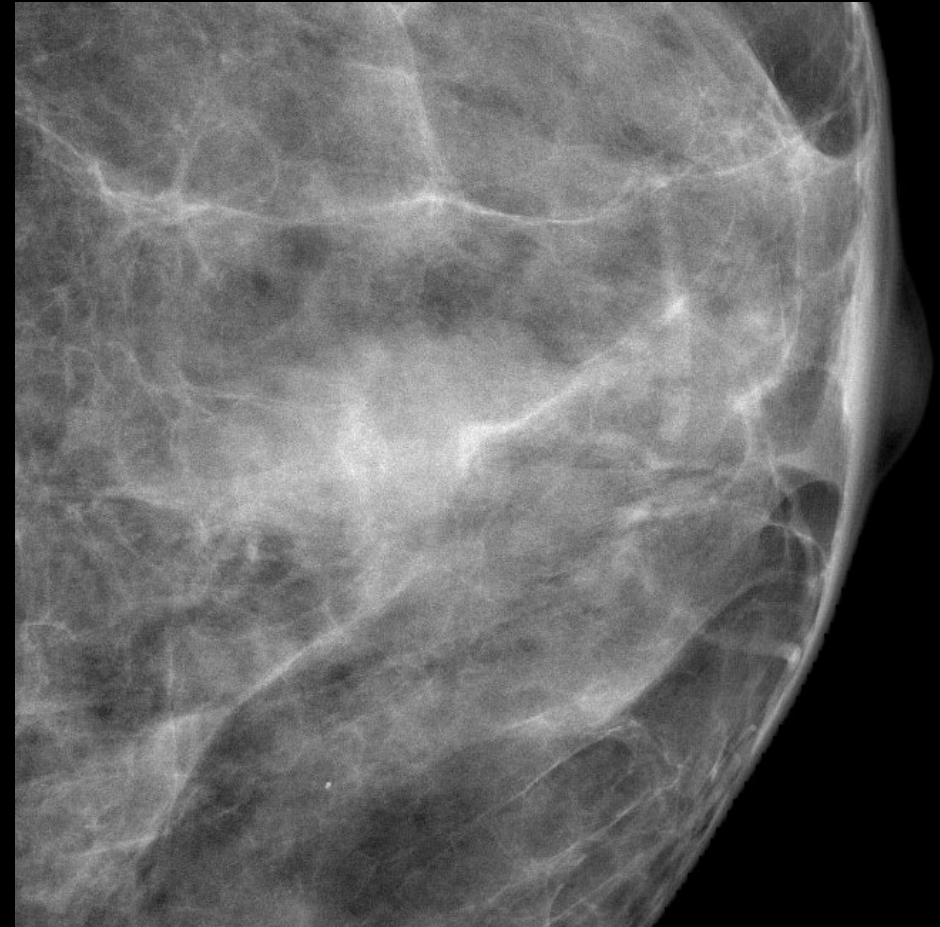
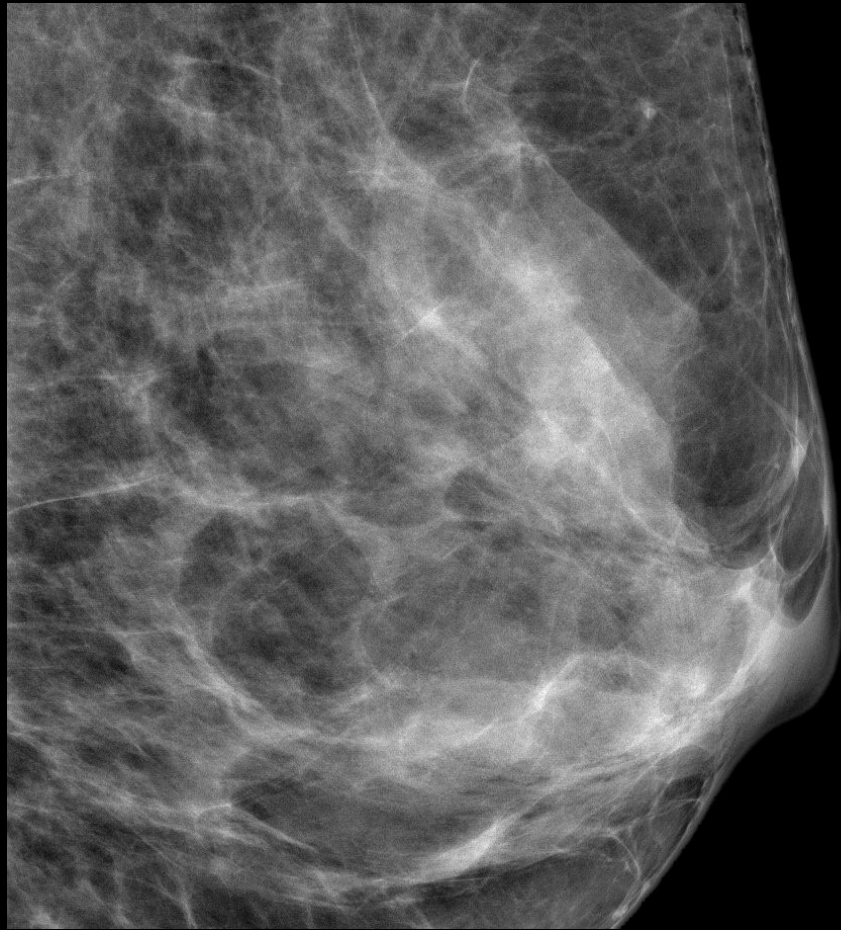
カテゴリー 1 / 1

正常

症例 11

65歳 乳腺散在

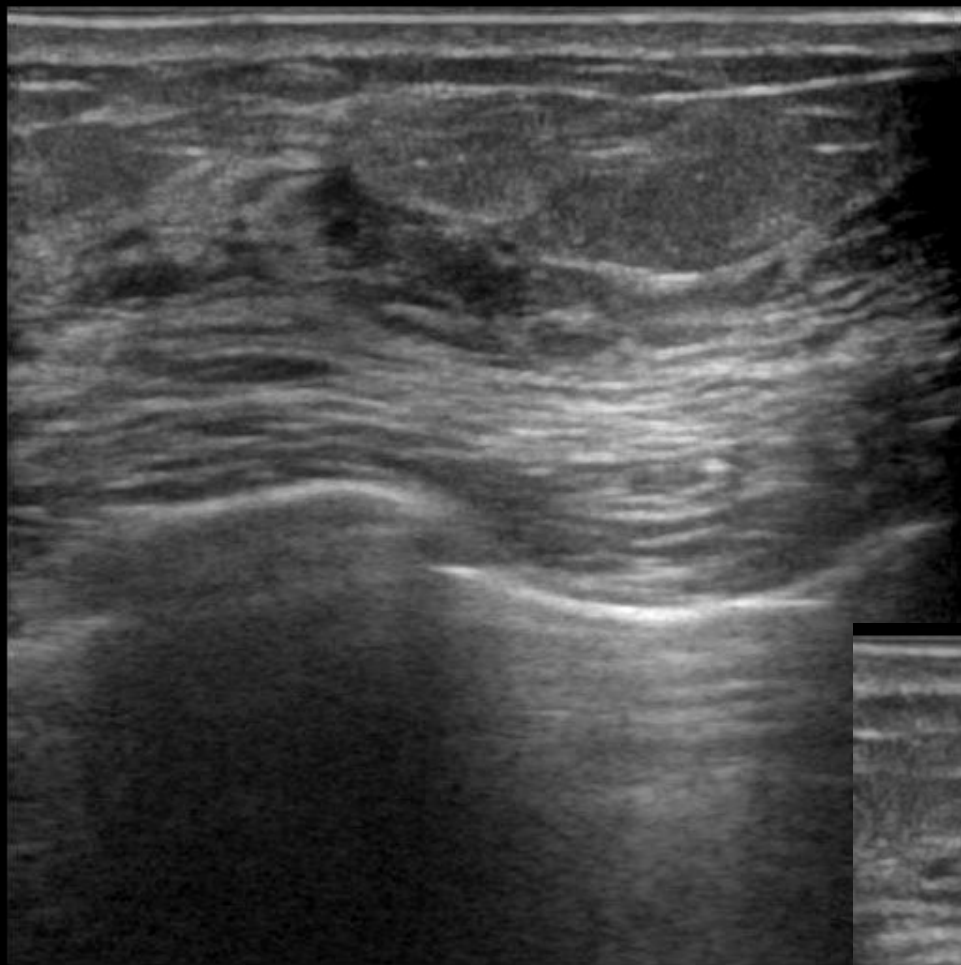




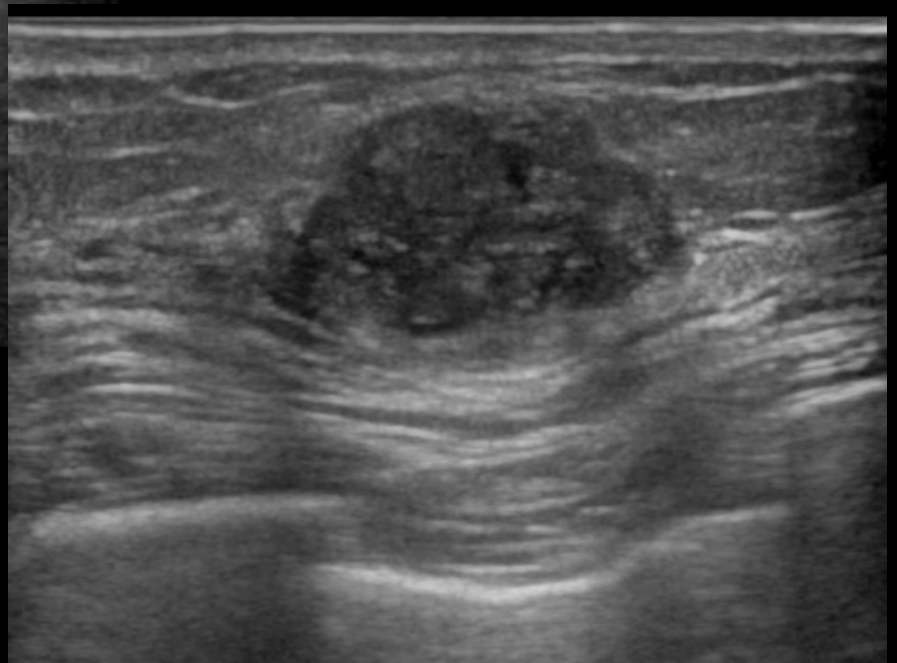
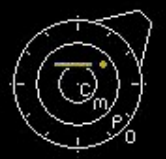FAD 境界不明瞭なやや高濃度の分葉形腫瘤

カテゴリー 3 4

H



- 0
.
.
.
- 1
.
.
- 2
.



FR:21
L75

BG:12 DR:70
HdTHI-P

症例 11

カテゴリー 1 / 3 4

粘液癌

T1cN0M0

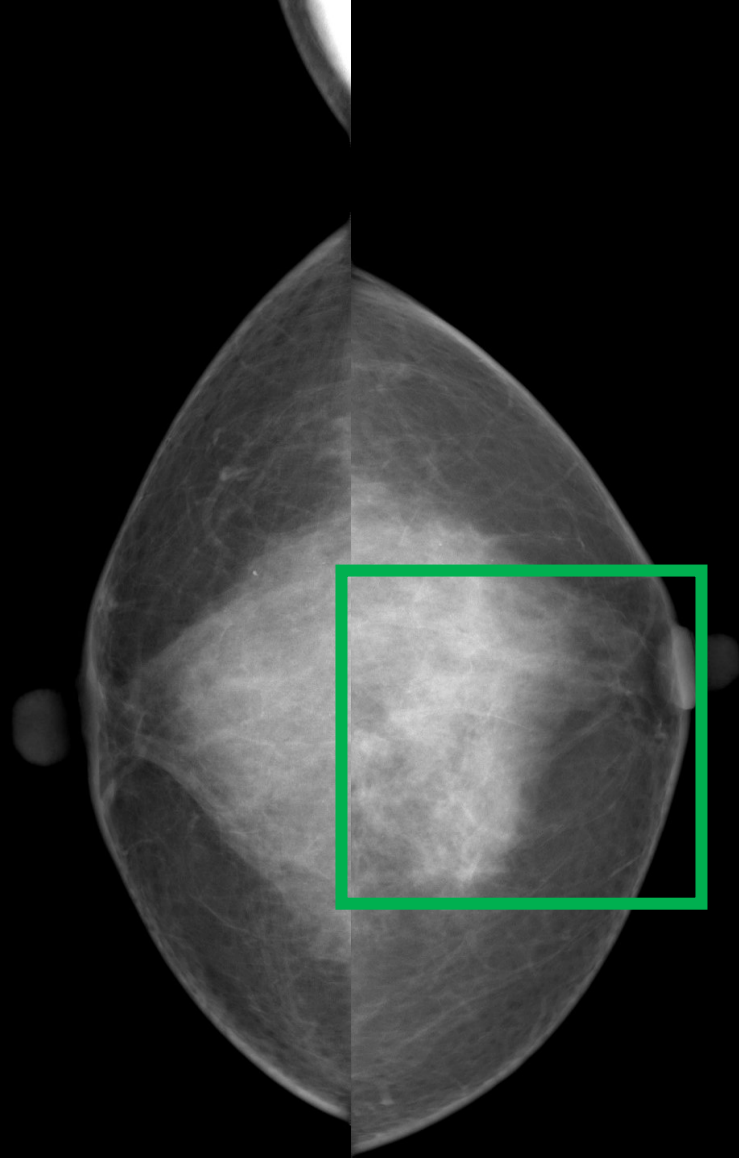
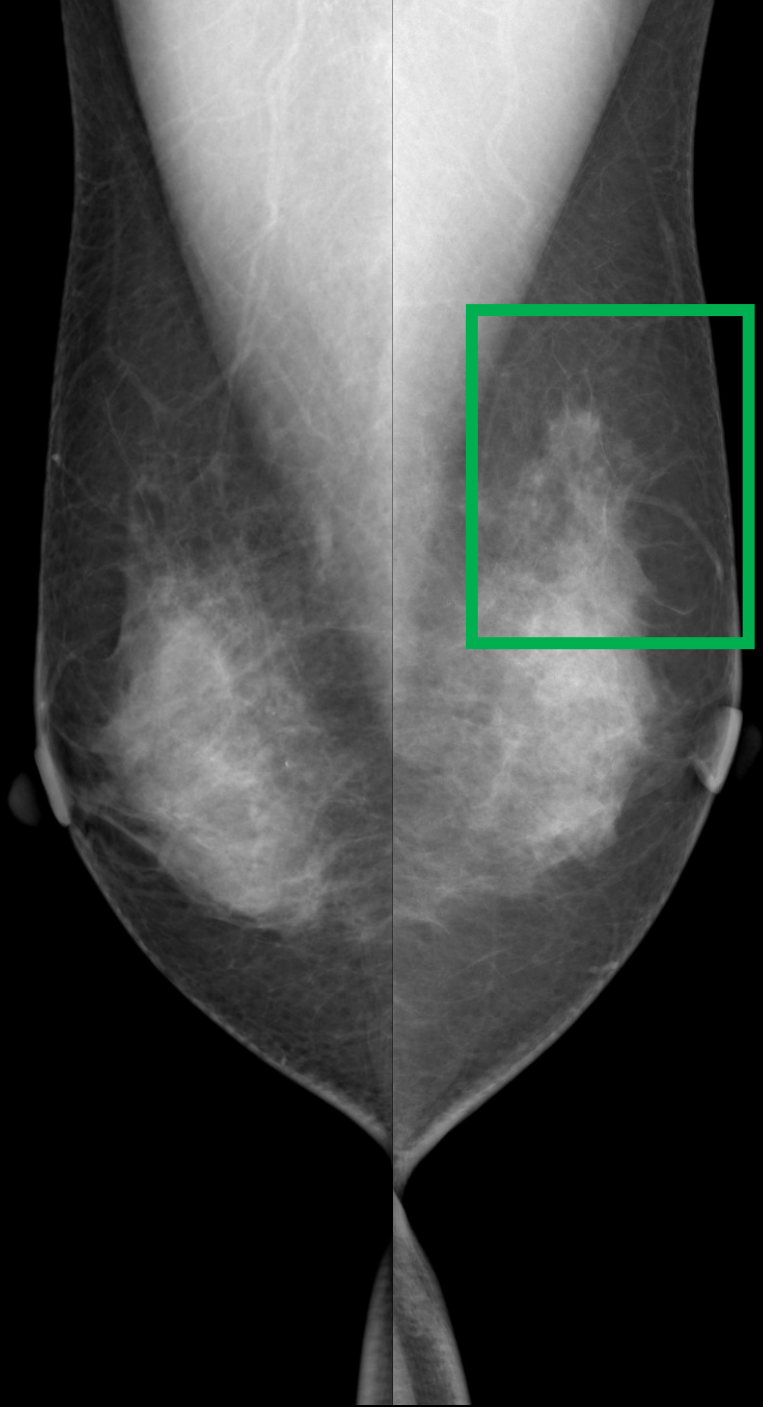
症例 12

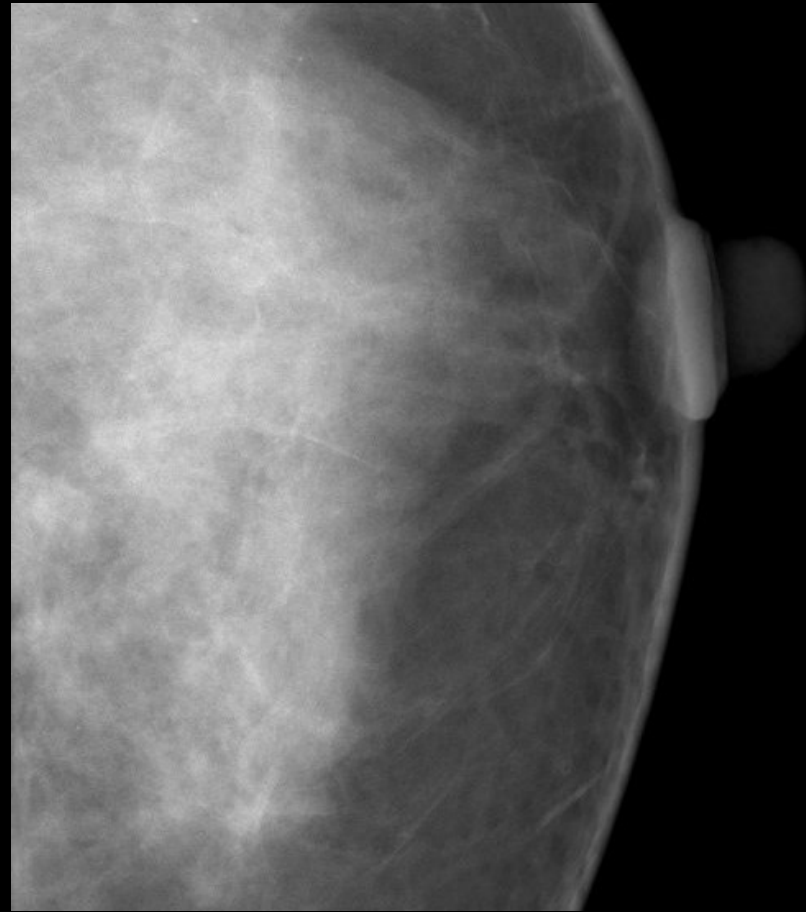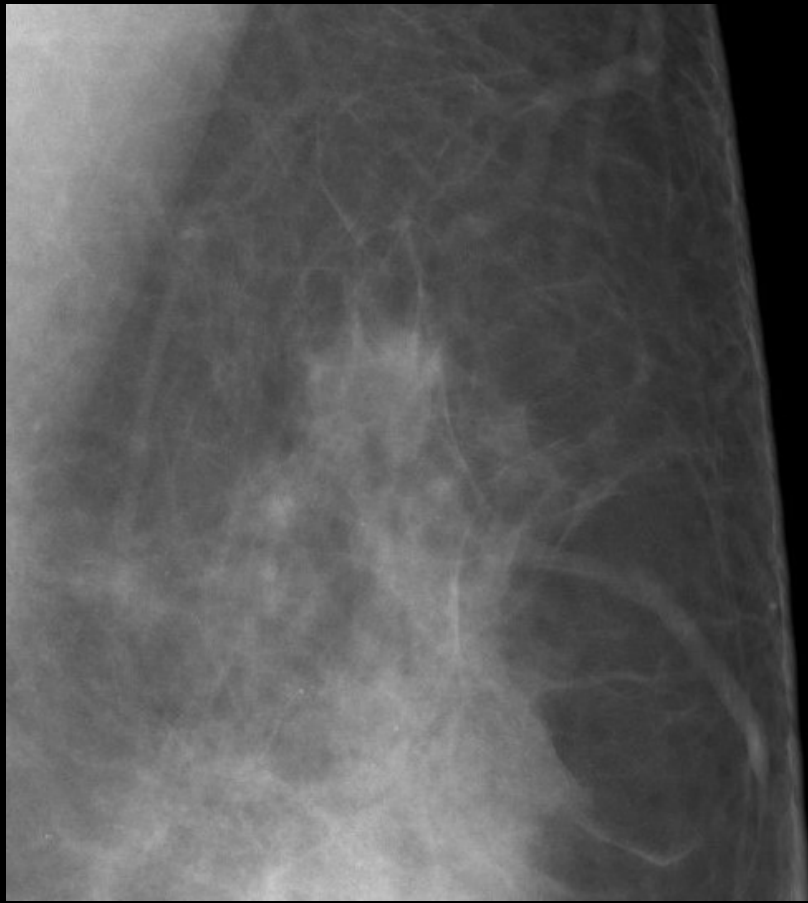カテゴリー 1 / 1

正常

症例 13

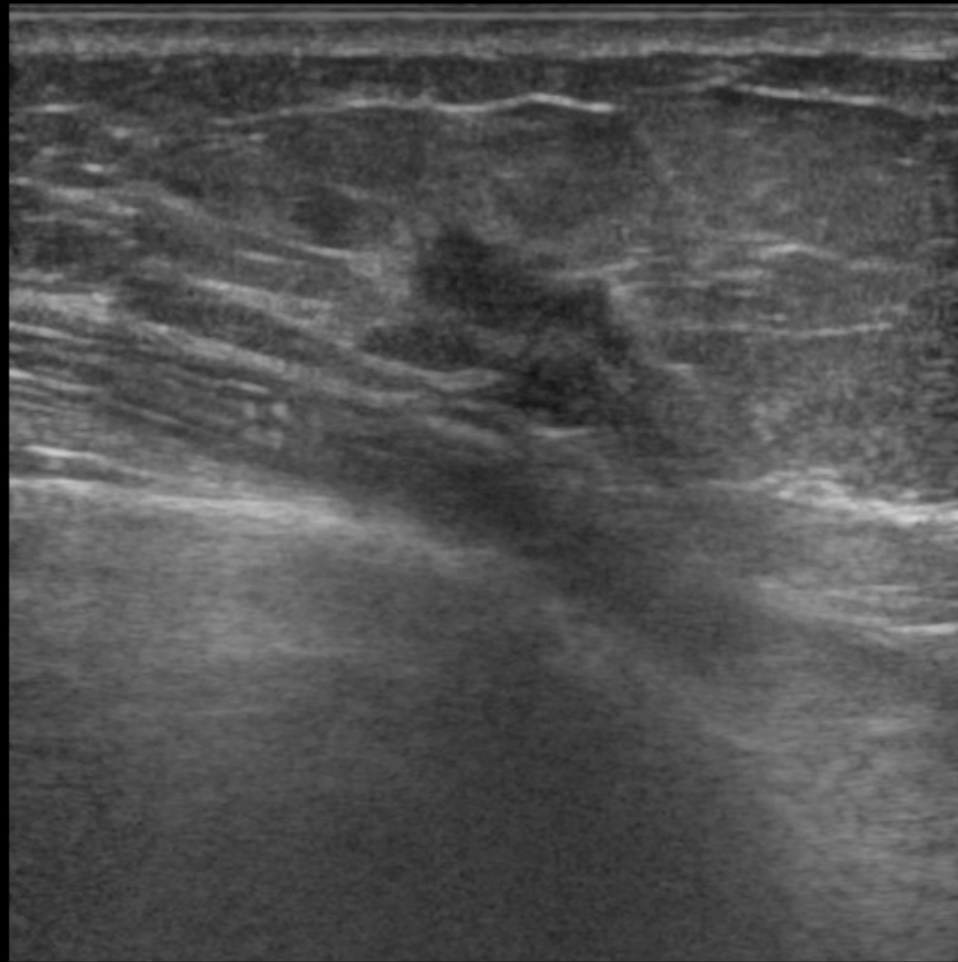
46歳 不均一高濃度





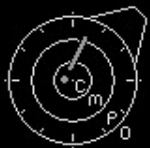微細鋸齒状の等濃度の不整形腫瘍

カテゴリー 4



H

- 0
.
.
.
- 1
.
▲
.
- 2
.
.
- 3
.
.
.



FR:21
L75

BG:12 DR:70
HdTHI-P

症例 13

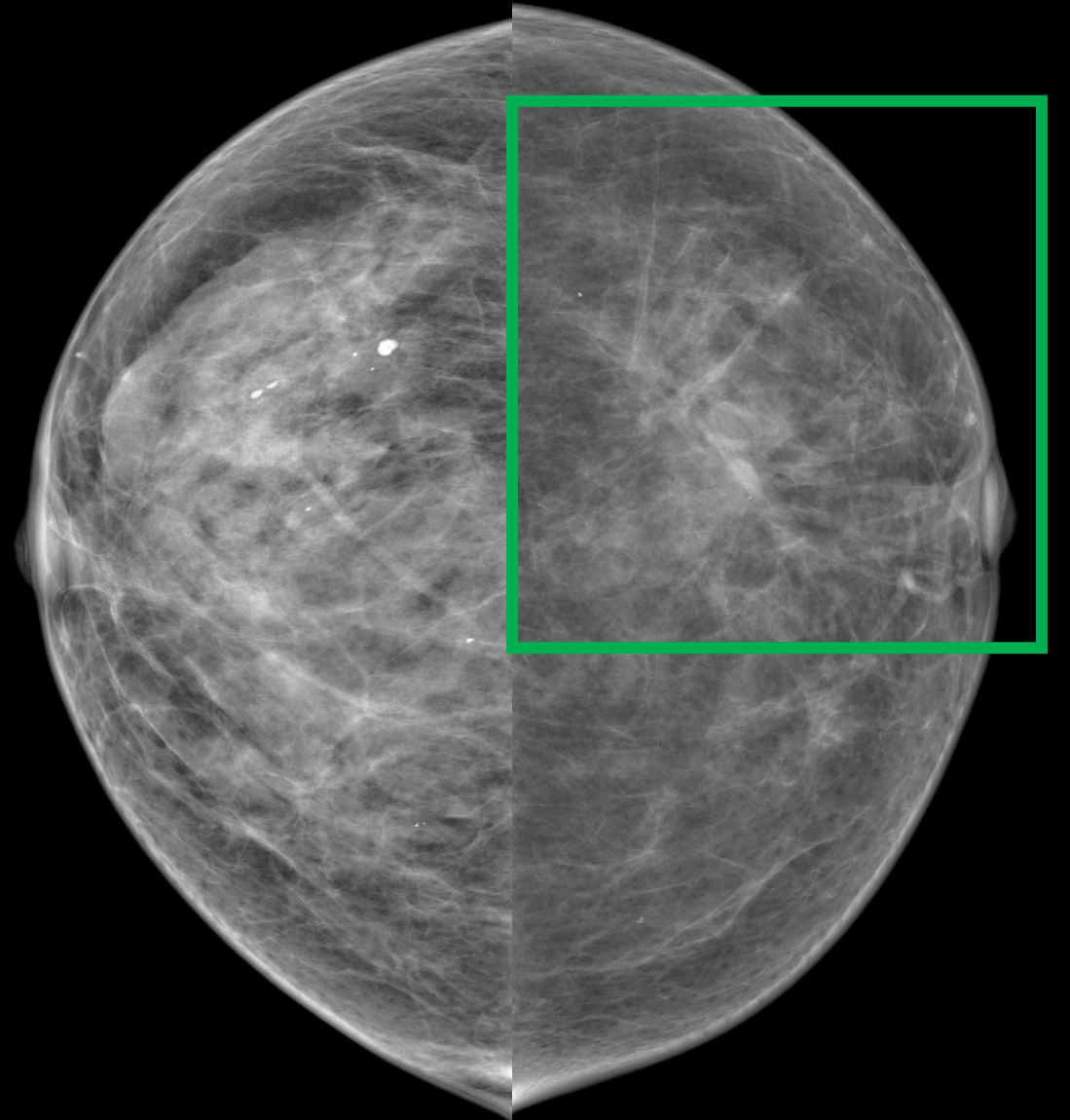
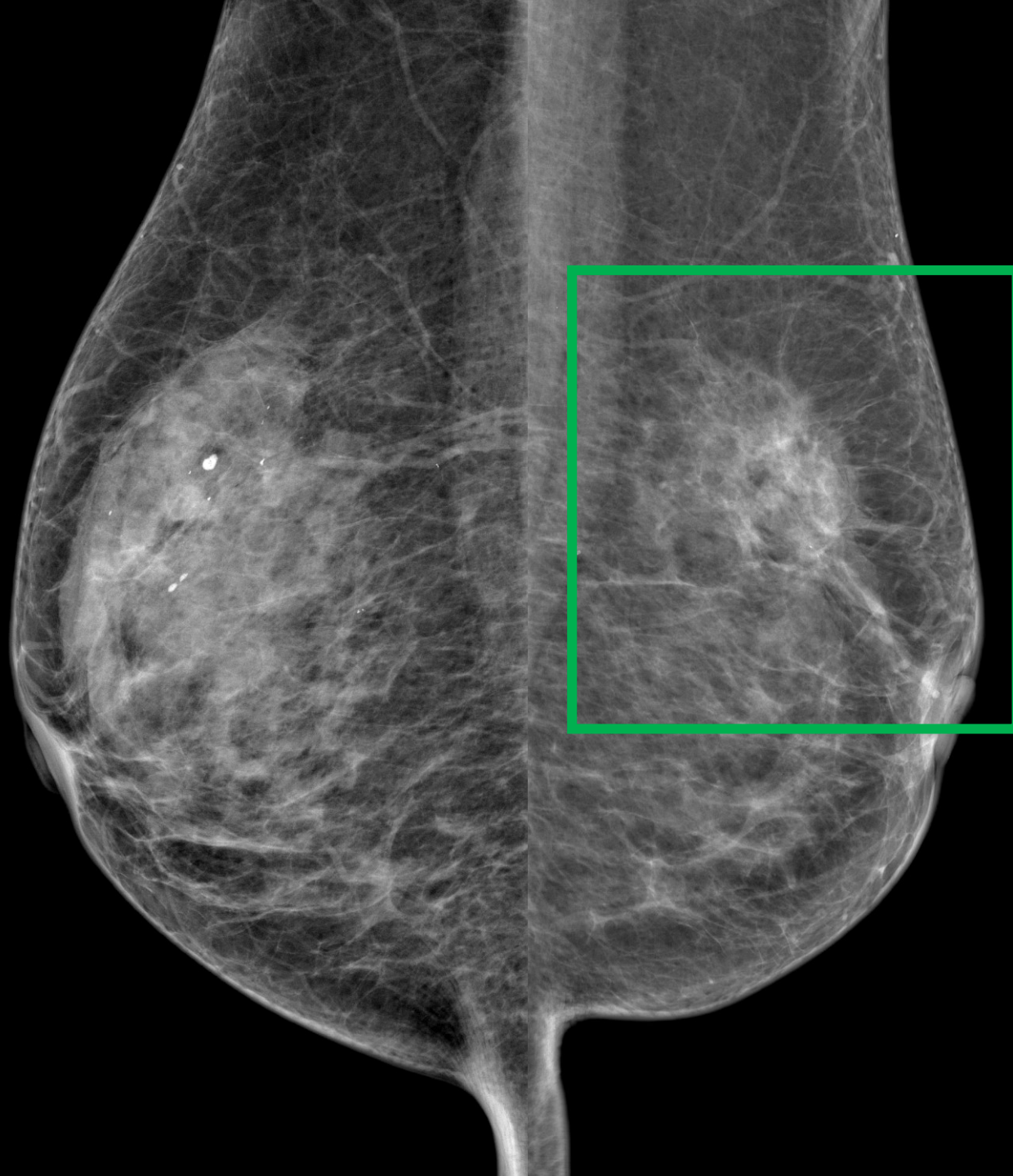カテゴリー 1 / 4

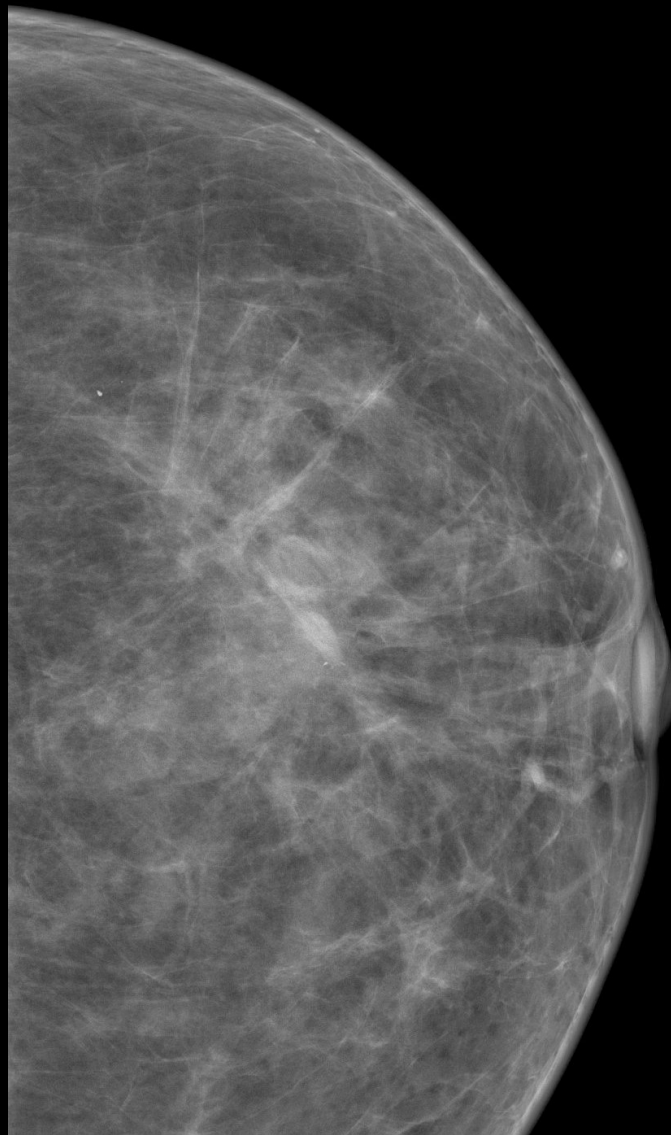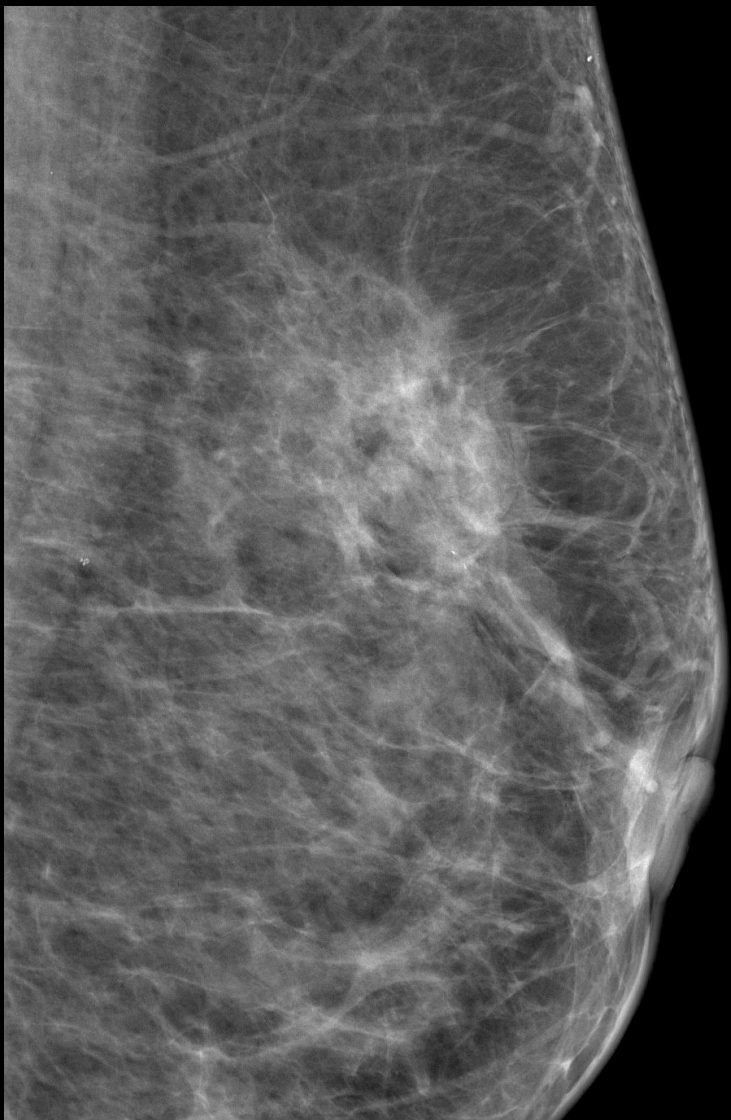
浸潤性乳管癌(硬性型)

T1cN0M0

症例 14

73歳 乳腺散在





構築の乱れ
カテゴリー 4

症例 14

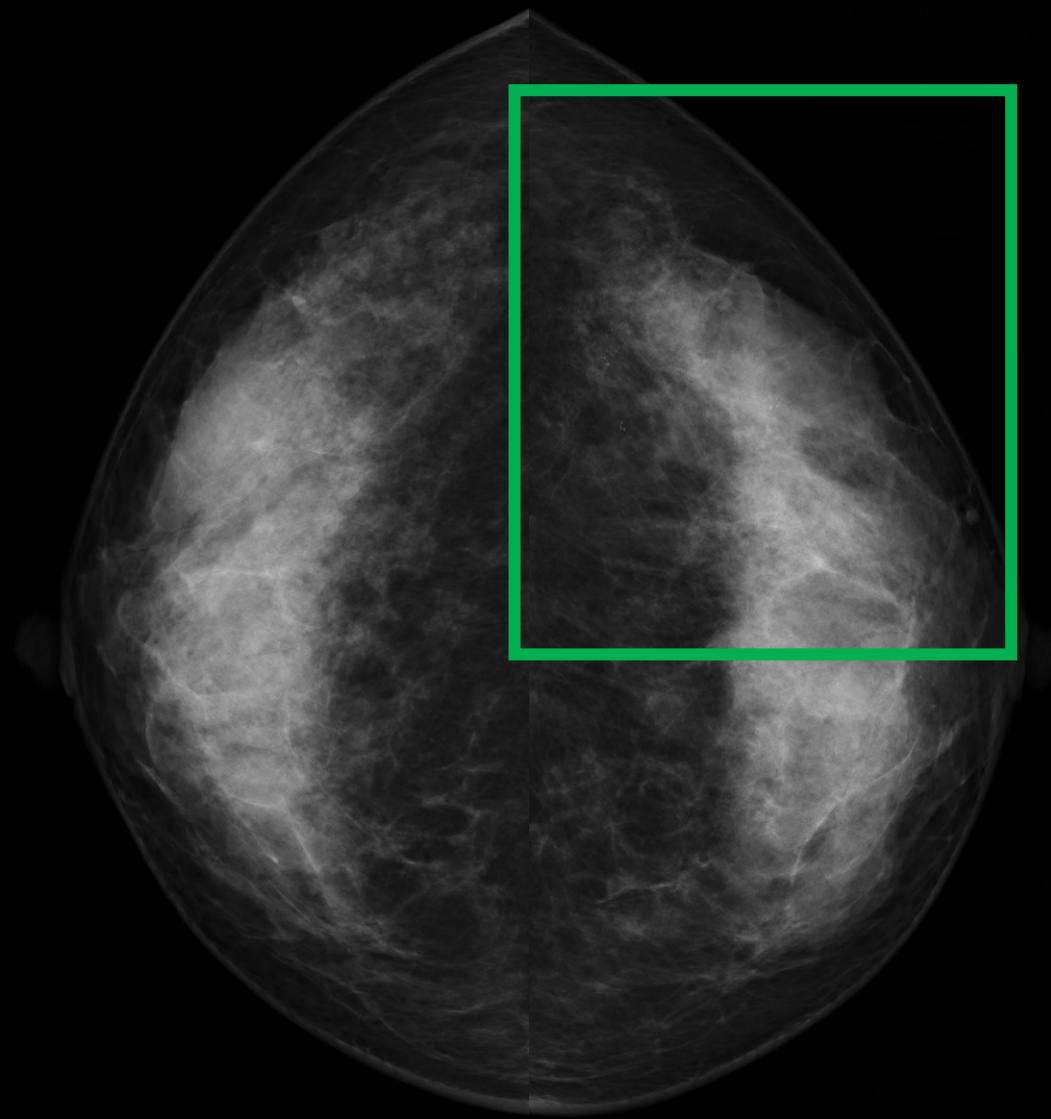
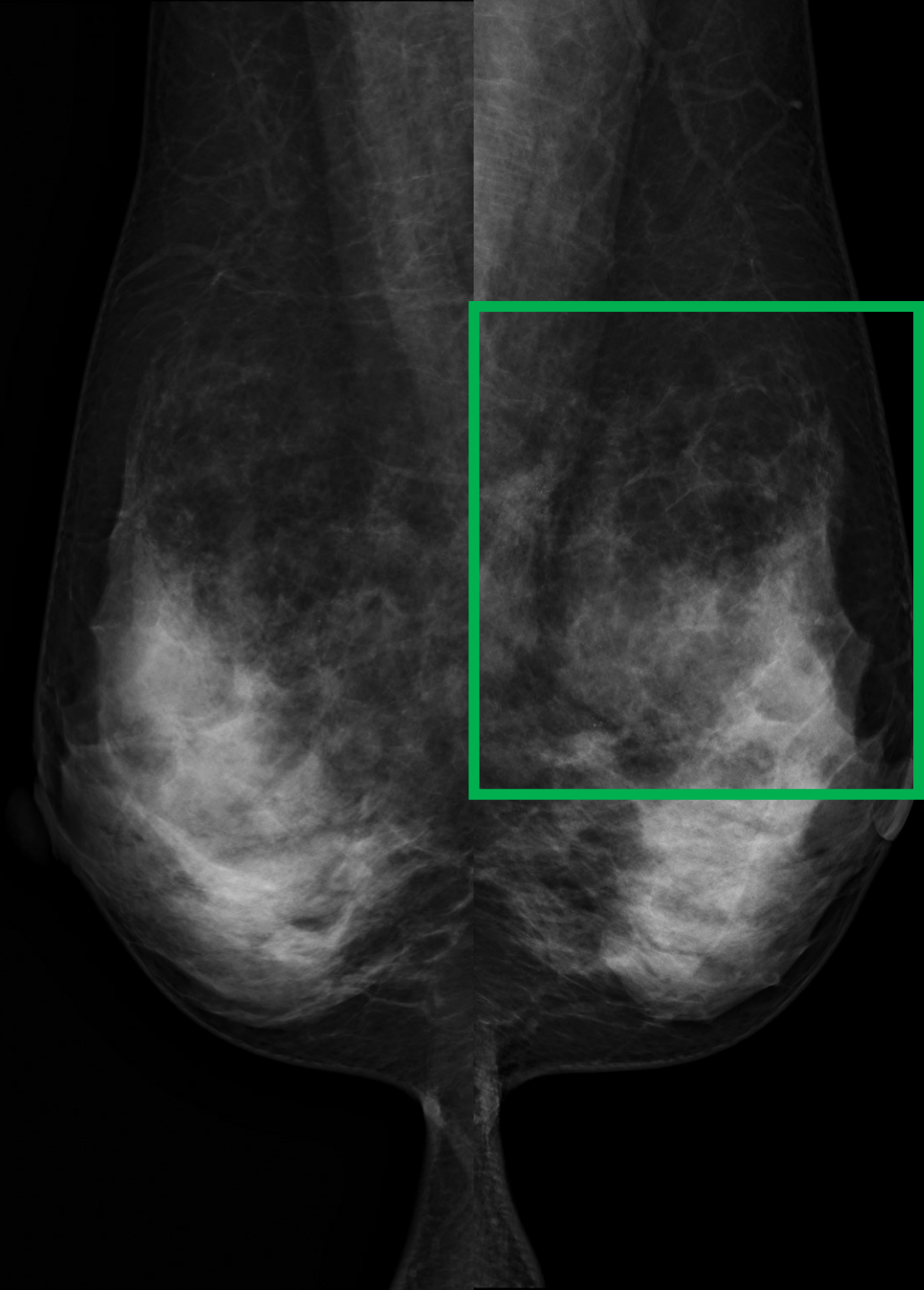
カテゴリー 2 / 4

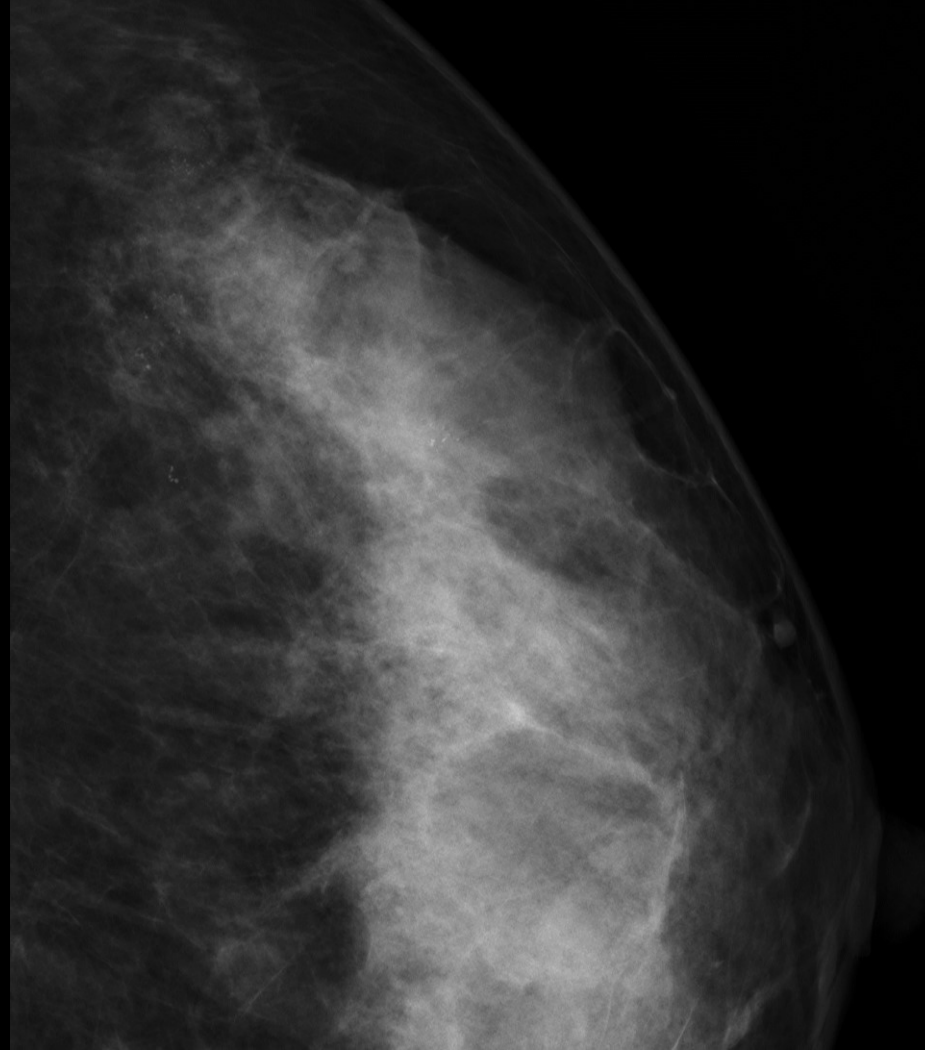
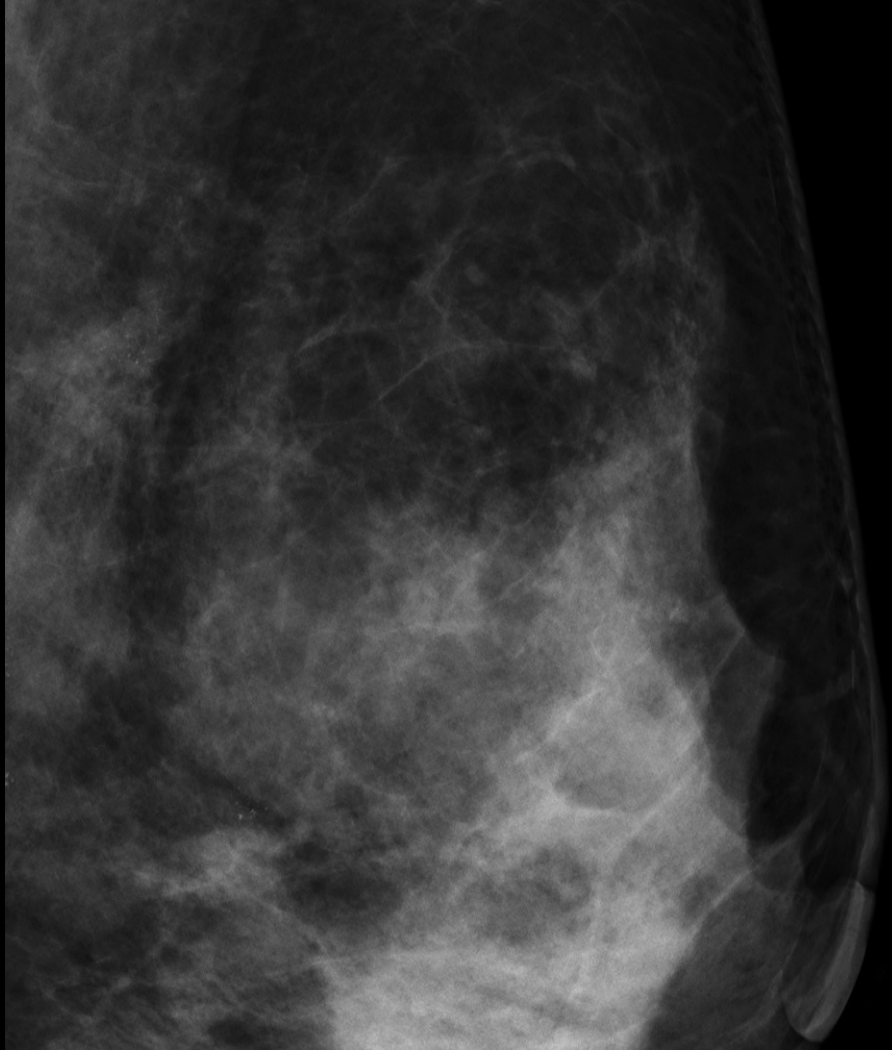
浸潤性小葉癌

T2N0M0

症例 15

46歳 不均一高濃度





淡く不明瞭、多形性石灰化、一部微細線状石灰化も混じる 区域性に分布

カテゴリー 4 5

症例 15

カテゴリー 1 / 4 5

非浸潤性乳管癌